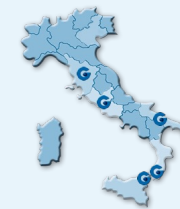




# Istituto Ortopedico del Mezzogiorno d'Italia

Messina, Reggio Calabria  
Italy

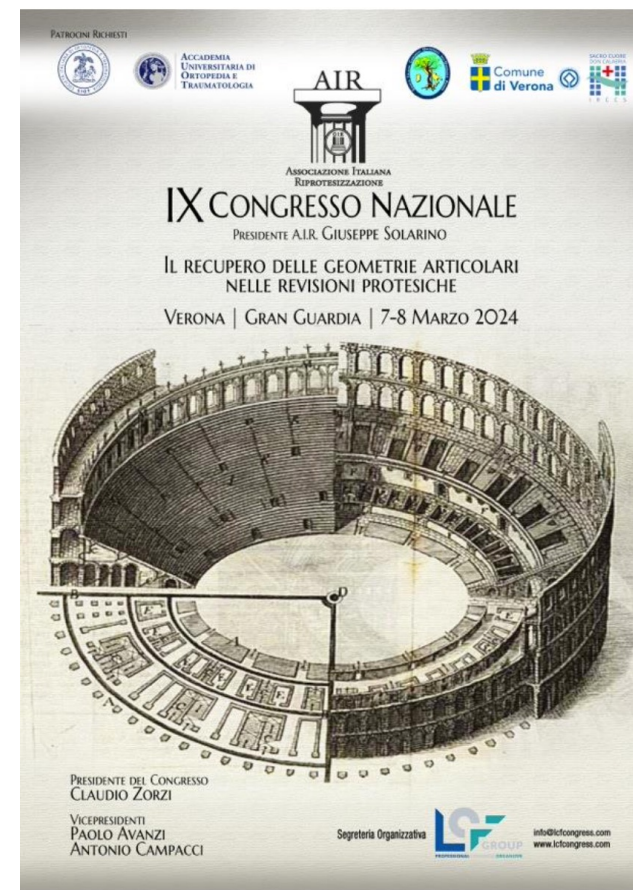

## Hip Section

P. Cavaliere  
F. De Meo  
G. Cacciola  
A. Bruschetta

Le infezioni protesiche con  
trattamento two step:  
ruolo dello spaziatore e  
della terapia antibiotica

P. Cavaliere



## DISCLOSURE

- G-21 s.r.l. – paid -consultant
- Medacta International - paid consultant
- Gruppo biimpianti – paid consultant



# Two-Stage Revision

*“TWO-STAGE Revision is considered as GOLD STANDARD treatment following PJI”*

## Advantages

- Allowing Uncemented reconstruction
- Better infection eradication
- Higher local [Abx]
- Muscle and soft tissue preservation

## Disadvantages

- At least two surgeries
- Higher Costs
- Poor functional Outcome

Q<sub>1</sub> Can we Improve the Functional Outcome of Two Stage Revision?

• **WELL PERFORMED articular spacer**

Q<sub>2</sub> “The optimal Spacer” Hand Made vs Preformed/molded

- Functional Outcome is similar;
- Reinfection rate is similar;
- Hand-Made Showed an High risk of fractures

Variable	Surgeon Made Spacers (Range)	Preformed Spacers (Range)	p Value
Mean follow-up (months)	43.7 (15-144)	48.9 (32-67)	0.49
Reinfection rate	6.0%	5.5%	0.76
Preoperative HSS score	36.4 (11.5-53)	33.4 (15-43.4)	0.53
Postoperative HSS score	84.3 (68-97.8)	81.8 (71.2-92.3)	0.50
Spacer complication rate	12.9%	12.4%	>0.05

Two-stage revision is characterized by an **high complications** rate

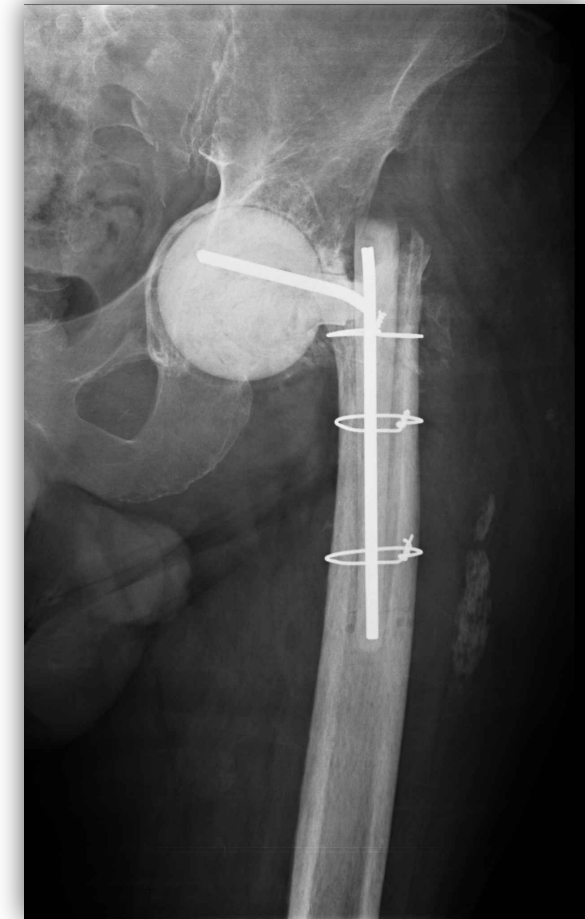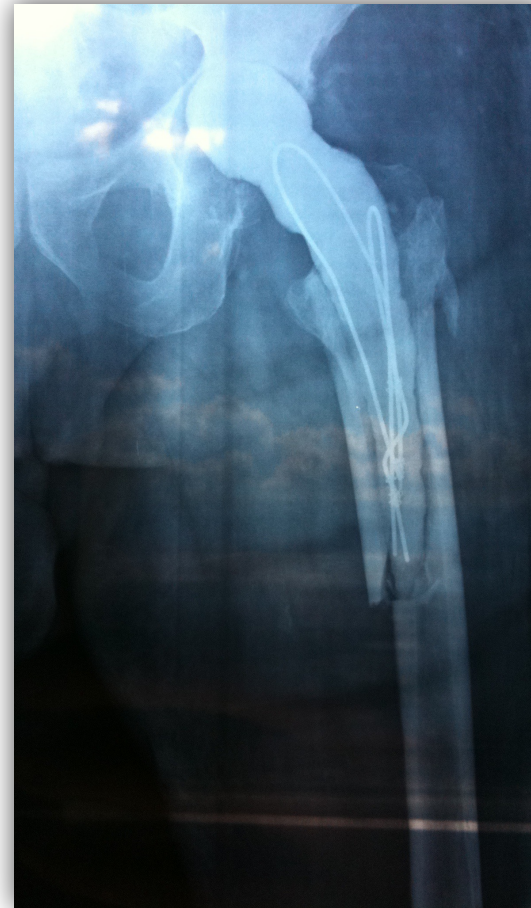## **Mechanical (10-40%)**

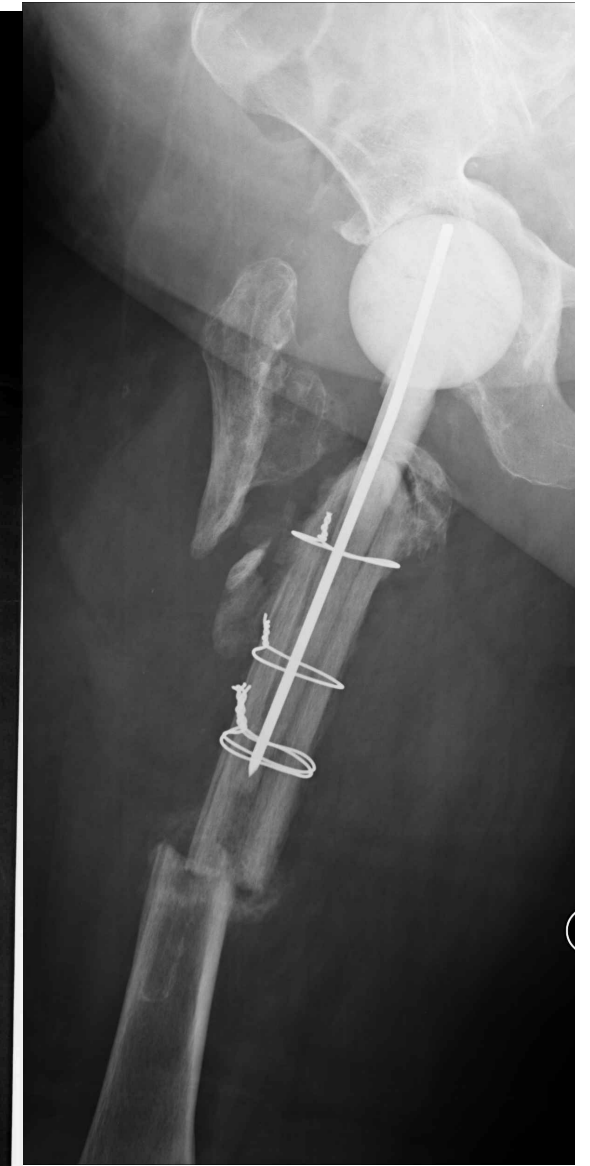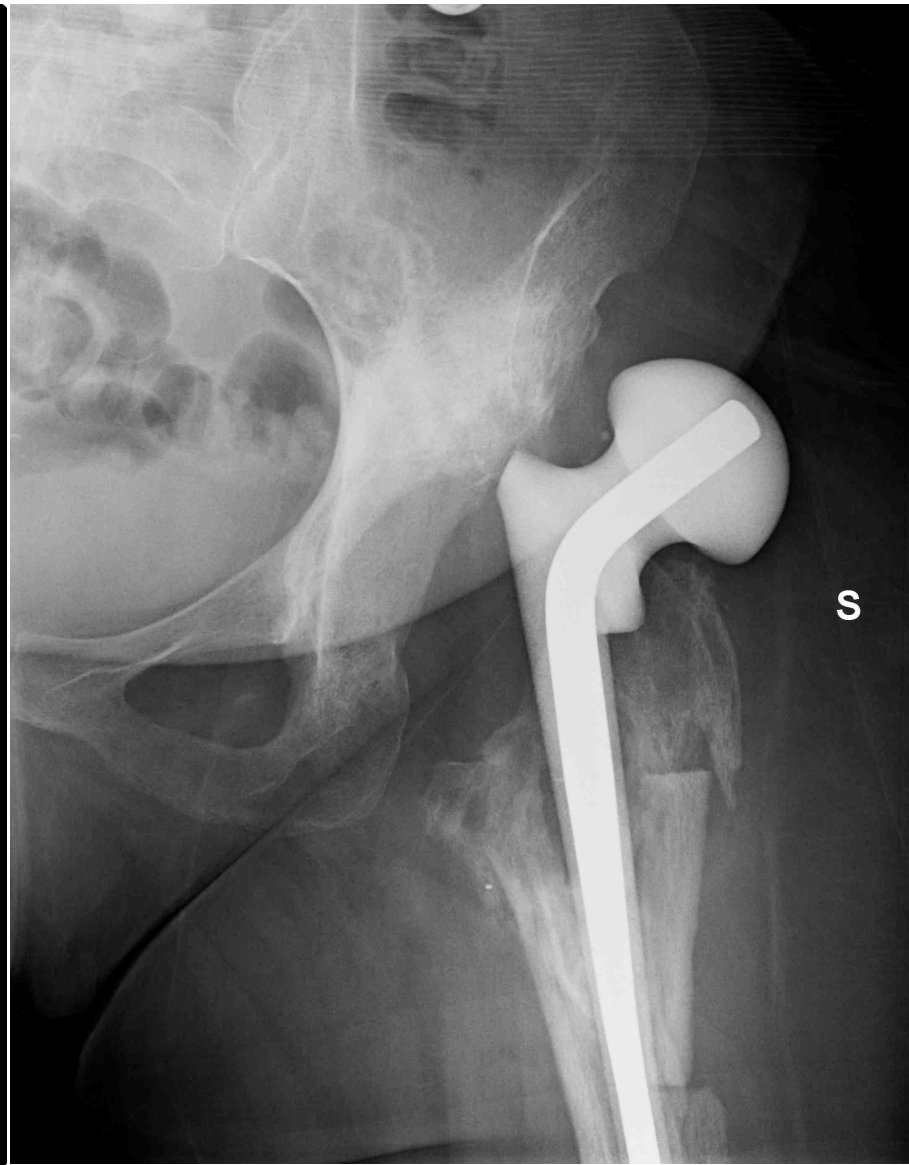
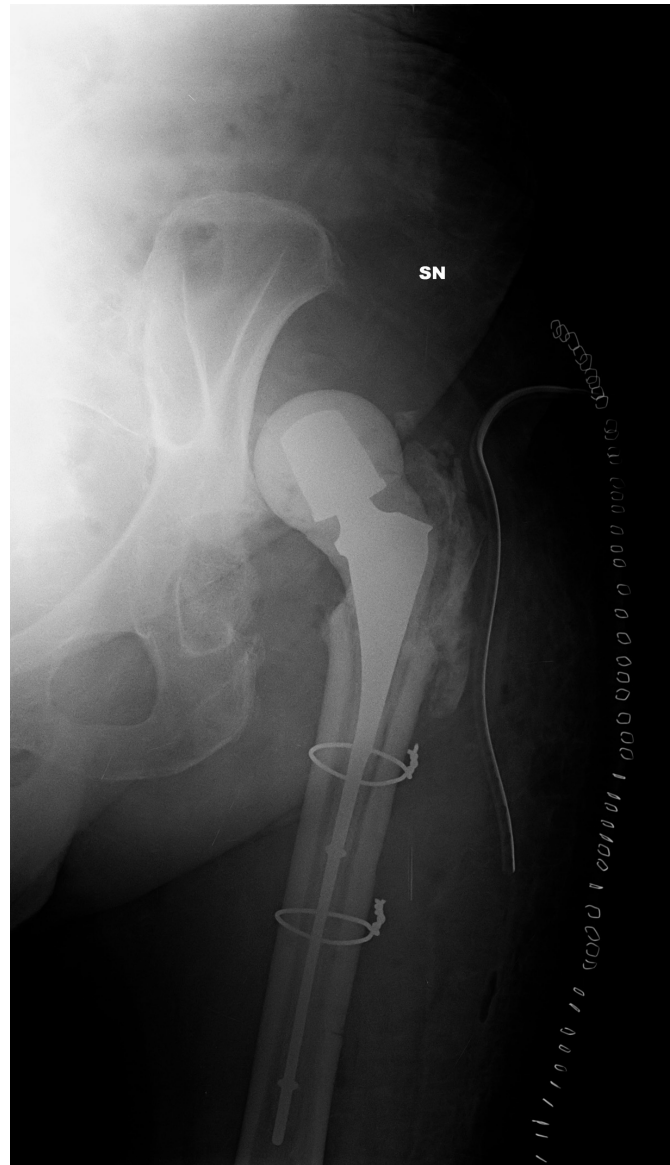
- Spacer Related
  - Fracture
  - Dislocation

## **Biological (0-10%)**

### **Septic**

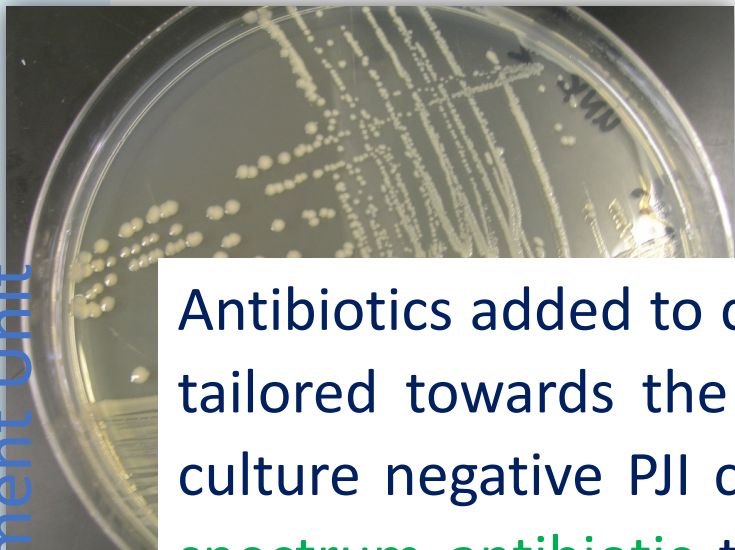- Persistent Inf.
- Recurrent Inf.







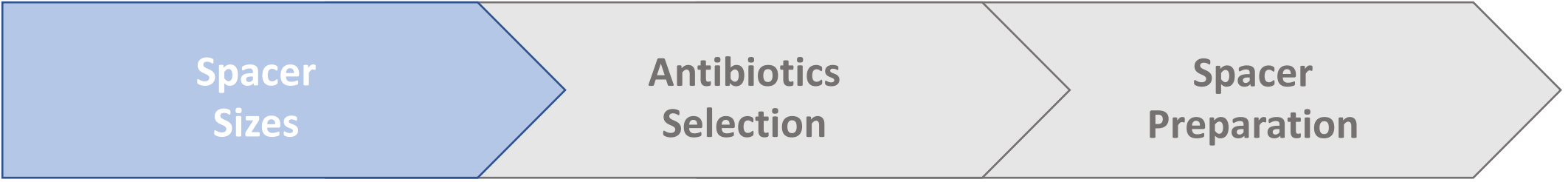# Background



Aspiration of a **joint** is **one of the most important aspects of the work-up** of a patient suspected of having an infected joint. There are numerous studies that demonstrate the utility of joint aspiration in aiding diagnosis of periprosthetic joint infection (PJI)

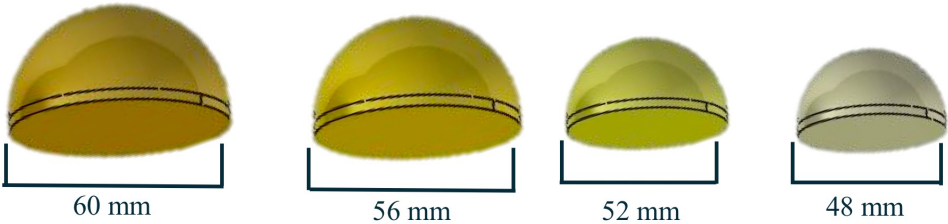
Antibiotics added to cement spacer during resection arthroplasty should be tailored towards the **causative organism** and its susceptibility. In case of culture negative PJI consideration should be given to addition of a **broad-spectrum antibiotic** to cement spacer to cover most potential pathogens causing PJI.

Serum testing	98.5%* (96.2-99.6)	100% (97.6-100)	100% (100-100)	97.5% (93.7-99.1)
Synovial fluid testing	<b>100%* (98.3-100)</b>	<b>100% (85.2-100)</b>	<b>100% (100-100)</b>	<b>100% (100-100)</b>
Intraoperative Findings	92.9% (80.5-98.5)	95.8% (78.8-99.9)	97.5% (85.1- 99.6)	88.5% (72.0-95.8)
Overall	96.9% (93.8-98.8)	99.5% (97.2-100)	100% (99.7-100)	96.7% (93.3-98.4)

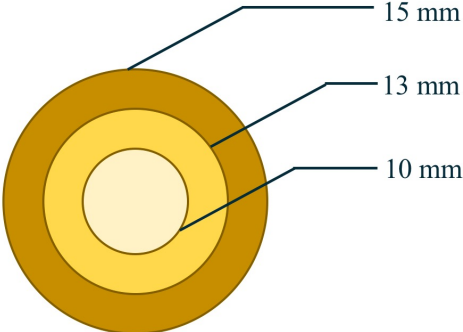


**Step ONE Selection of Optimum Head and Stem Measures:** Selection of Head Diameter, Stem Thickness and Length. **36 different combinations are possible.** The concept of modularity is though to re-establish the normal anatomy/biomechanics of the hip during the interval period.


**Acetabular Heads Dm.**

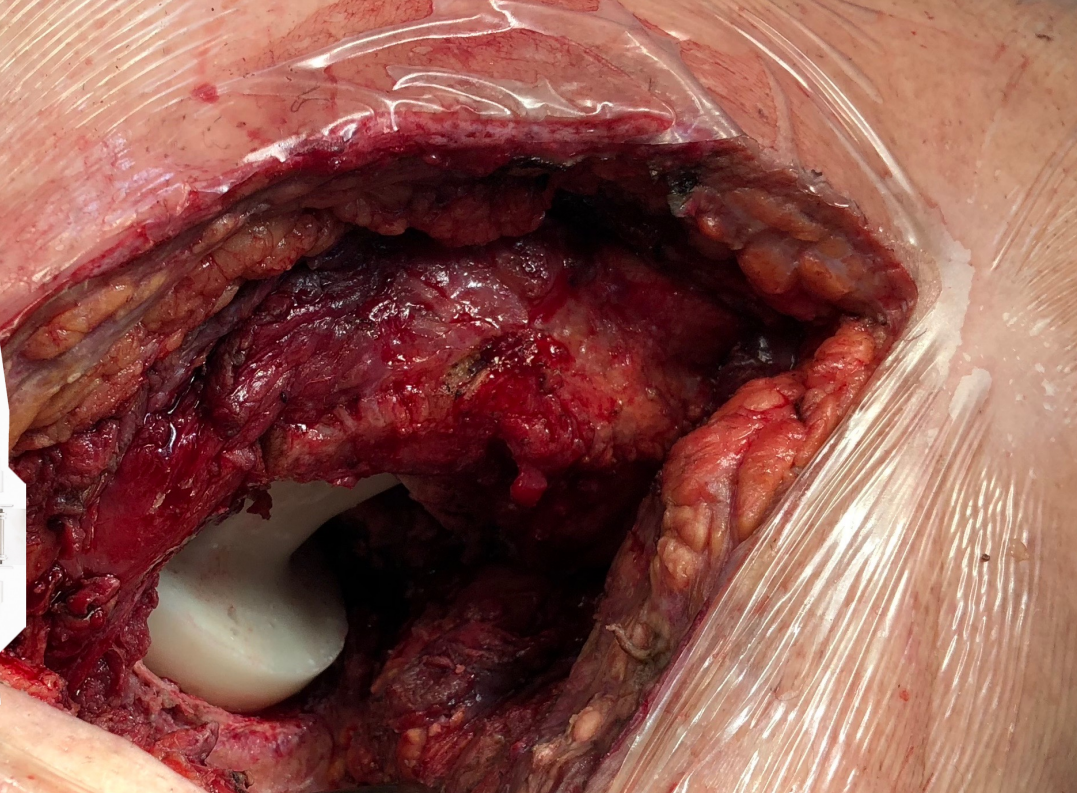
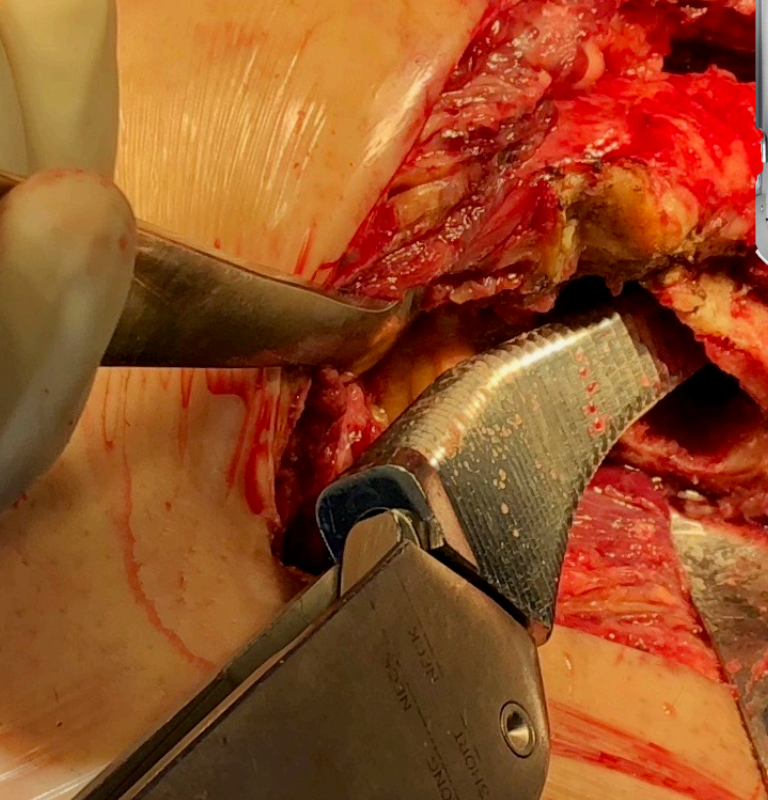

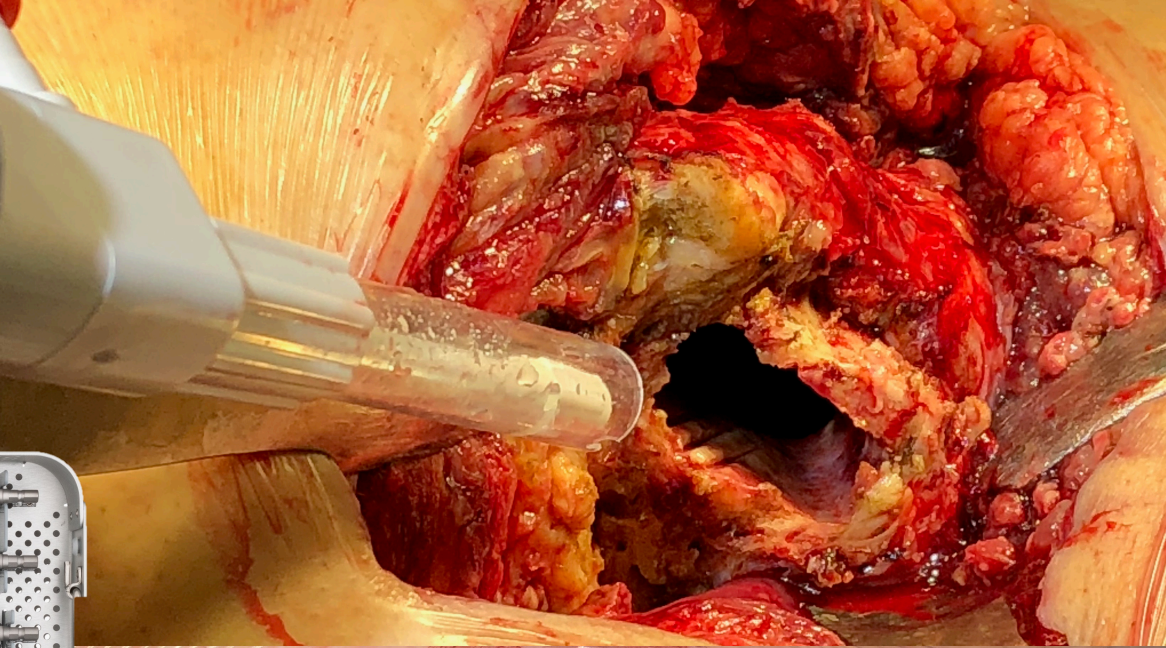
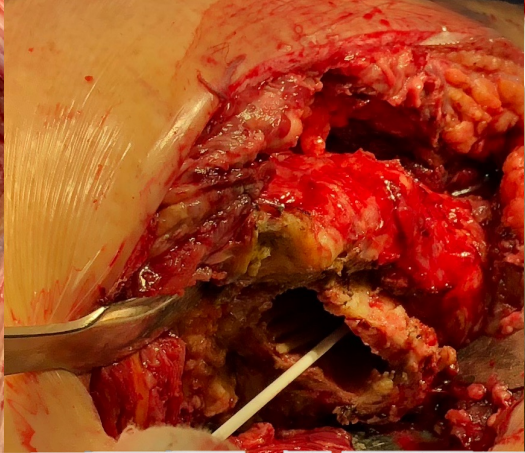
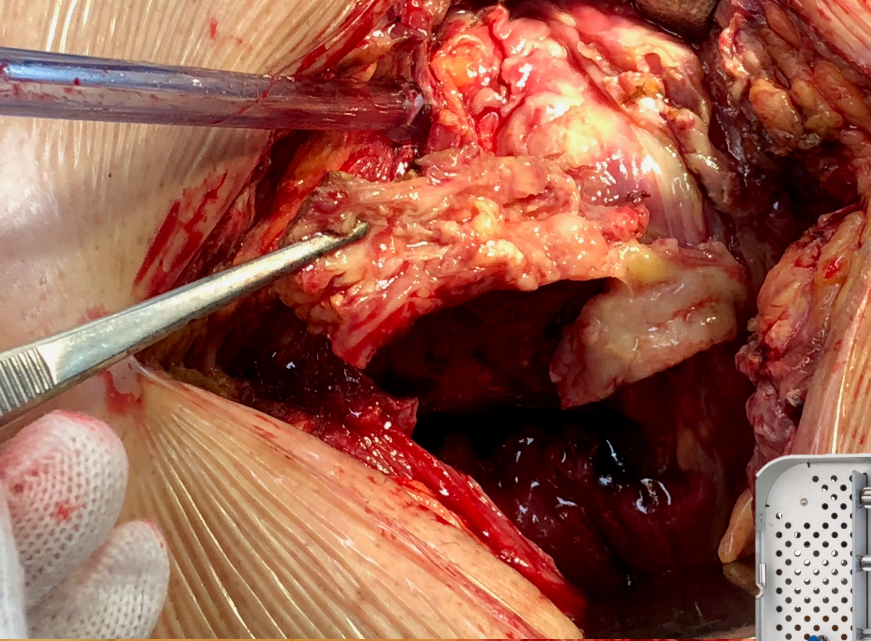


**Femoral Stem Dm.**



**Stem Length**



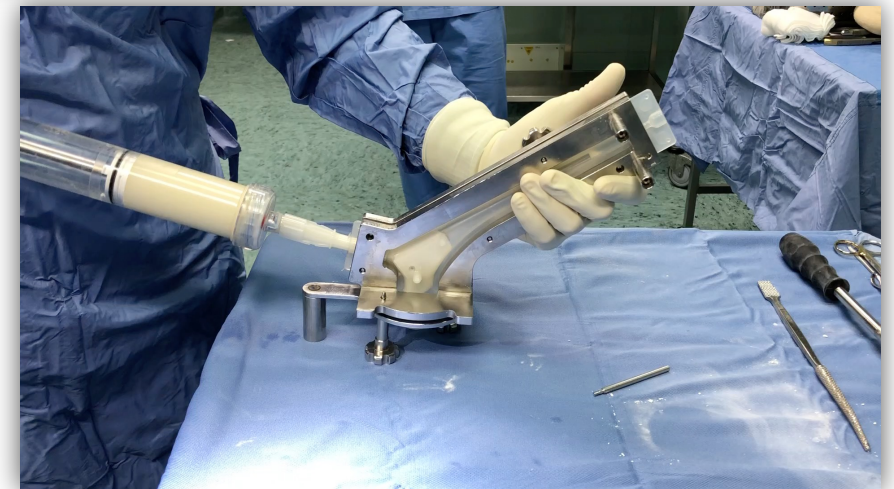
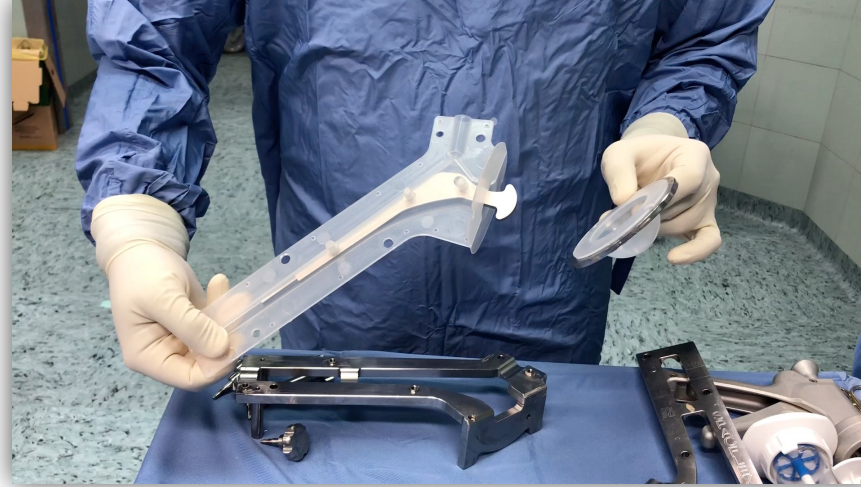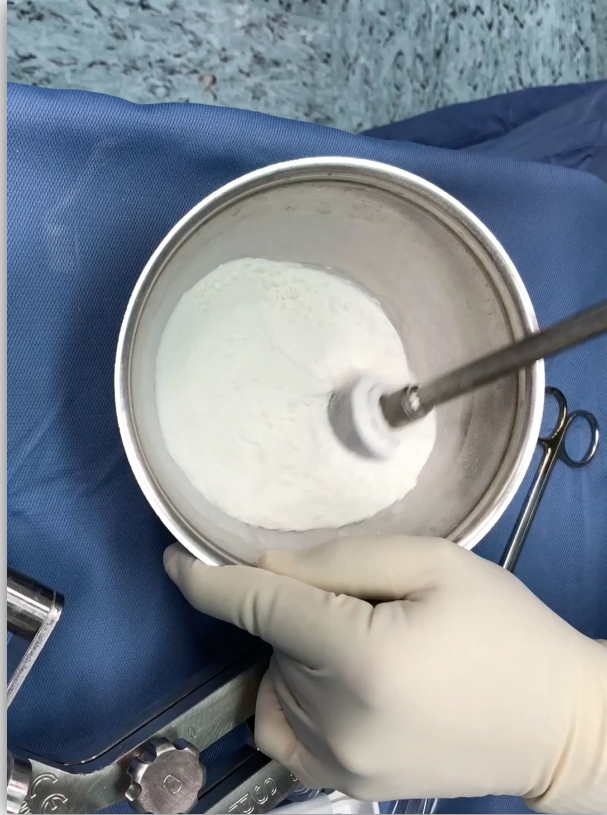




Spacer  
Sizes

Antibiotics  
Selection

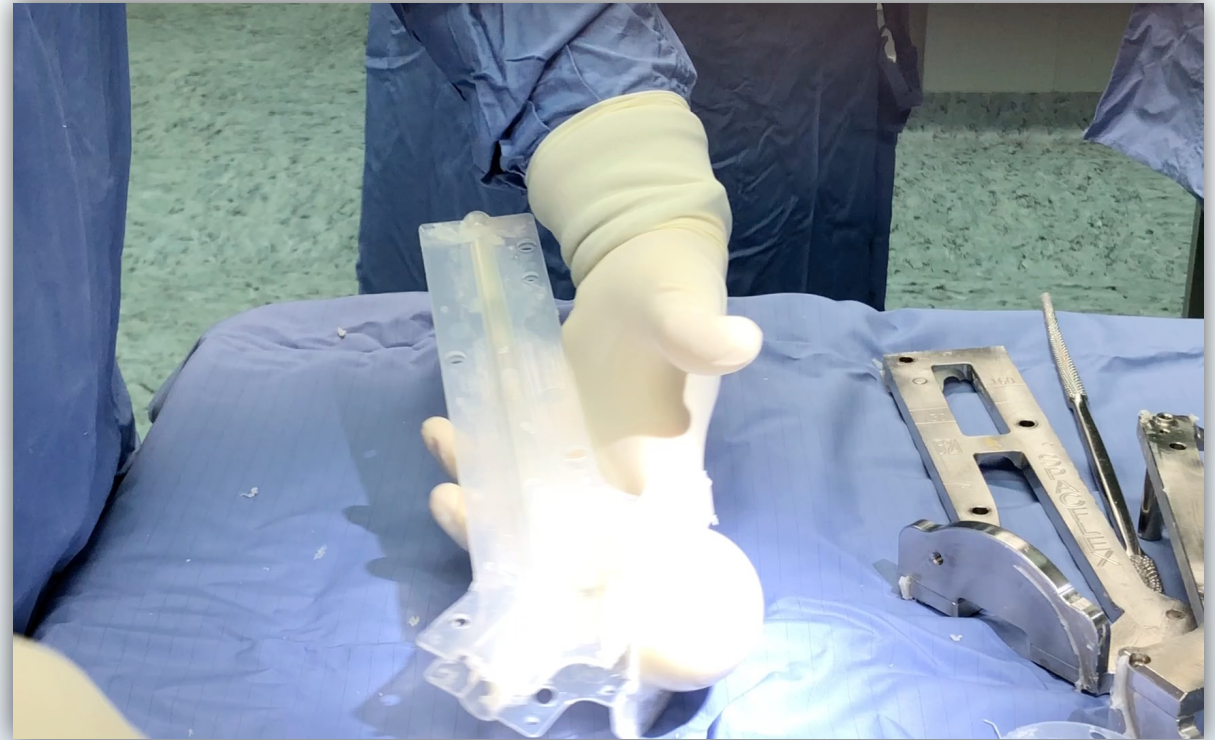
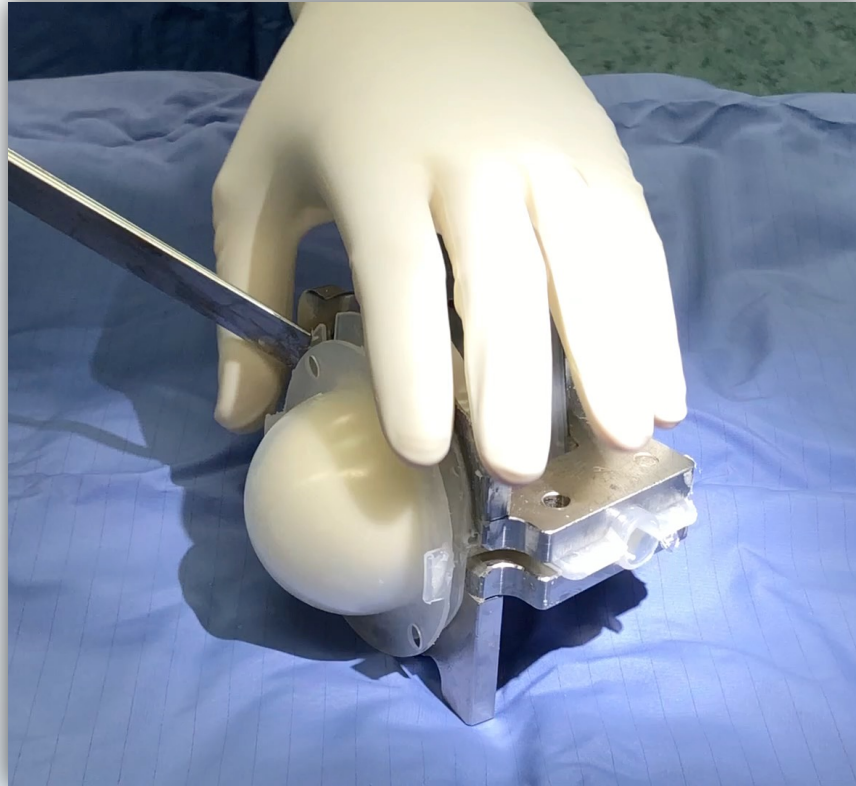
Spacer  
Preparation



Spacer  
Sizes

Antibiotics  
Selection

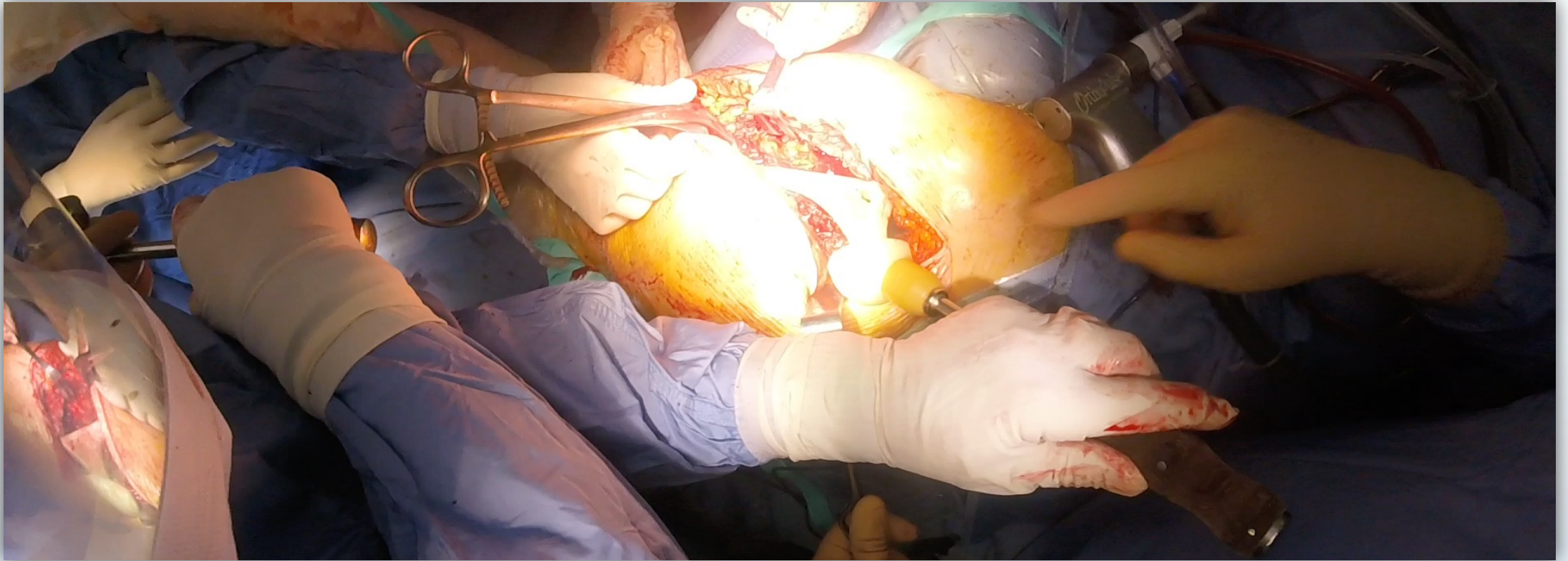Spacer  
Preparation

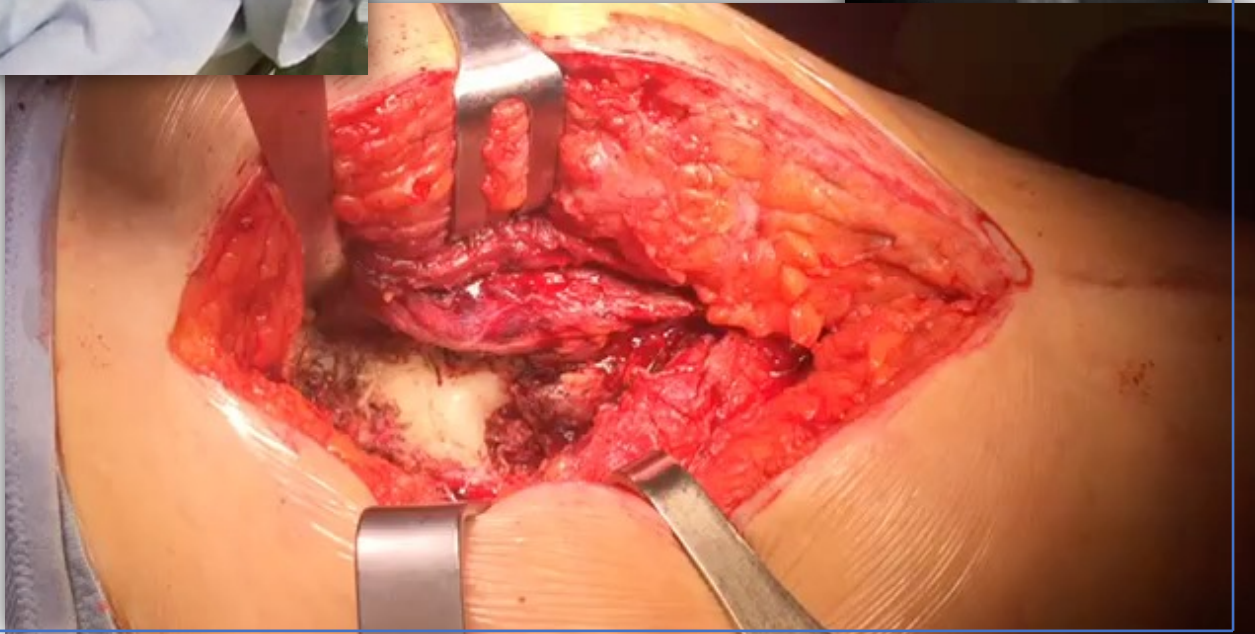
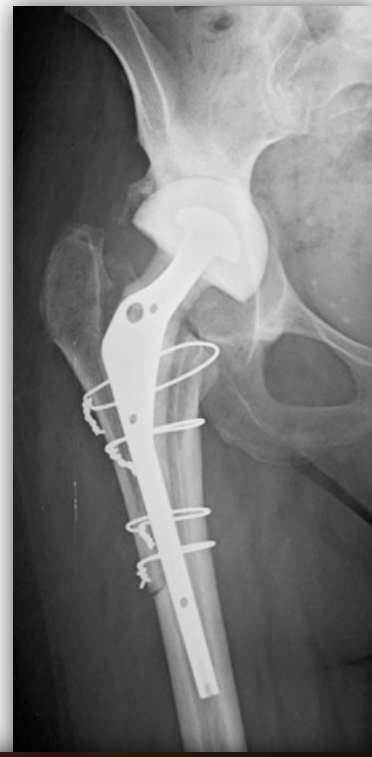
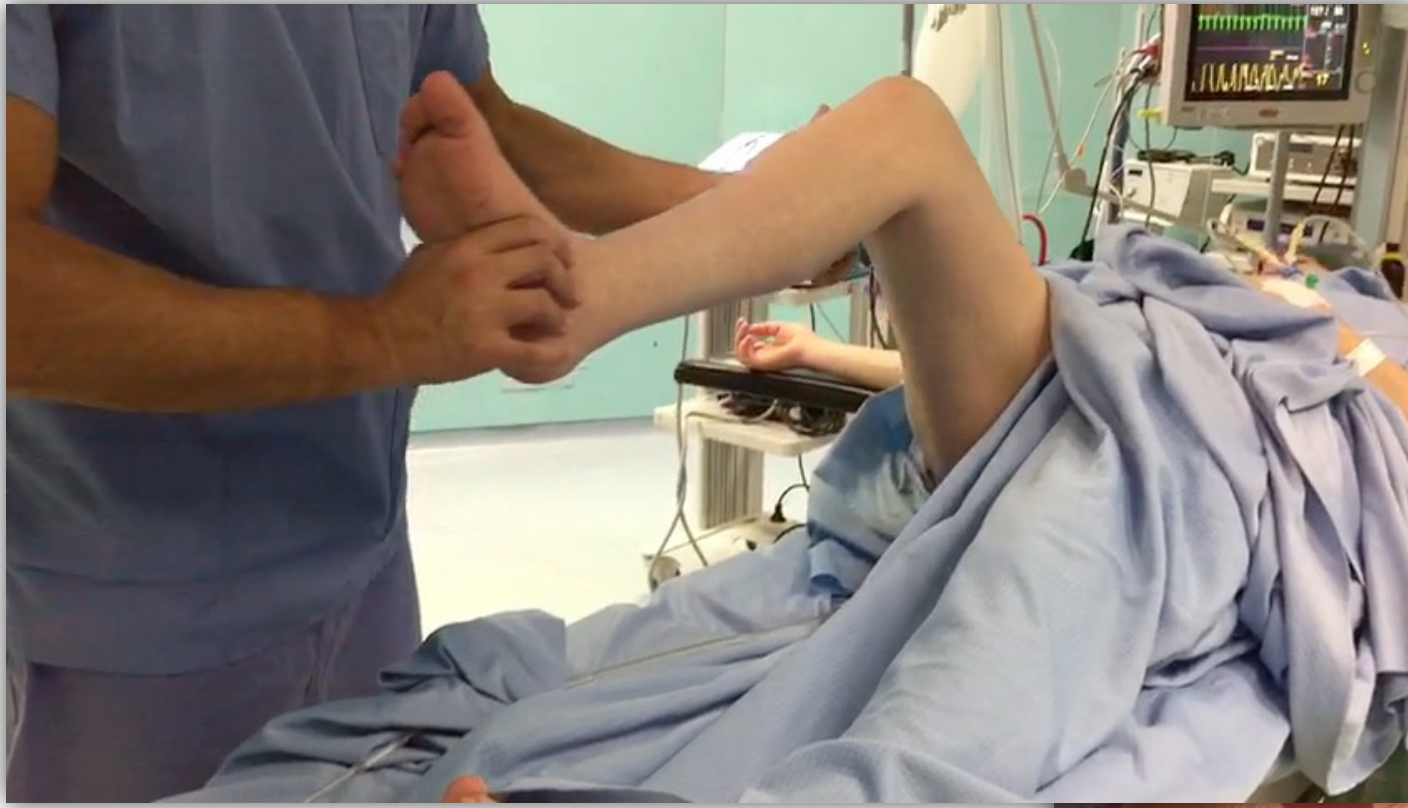
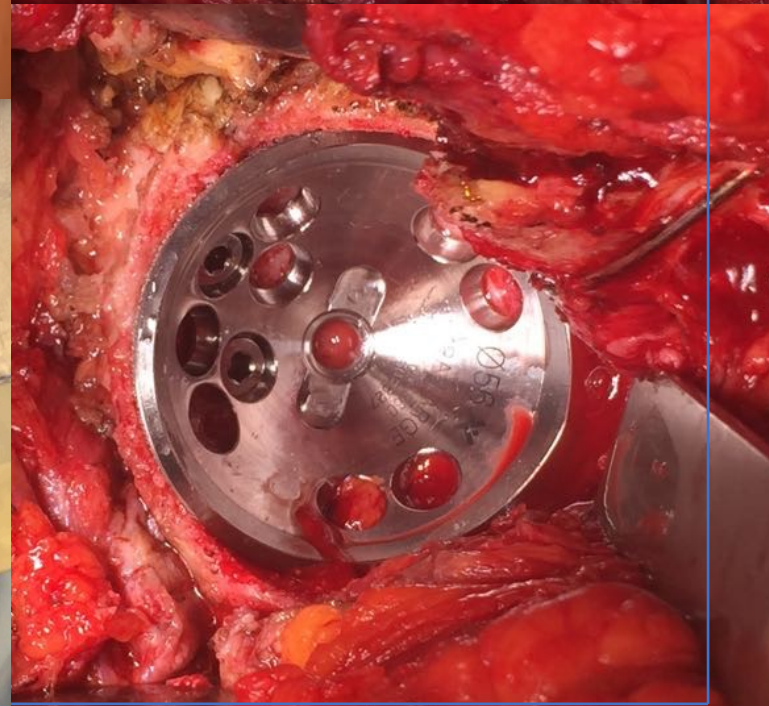
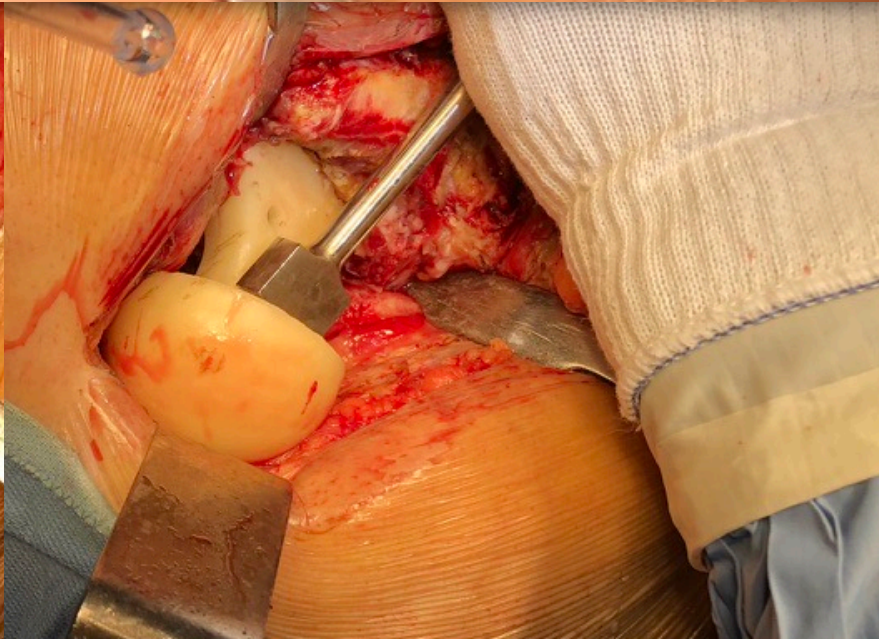
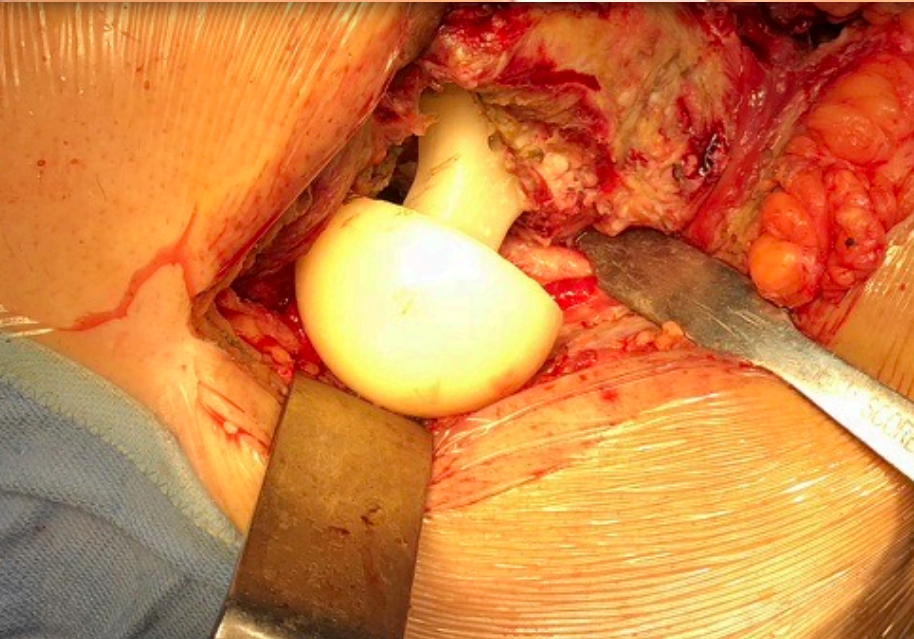
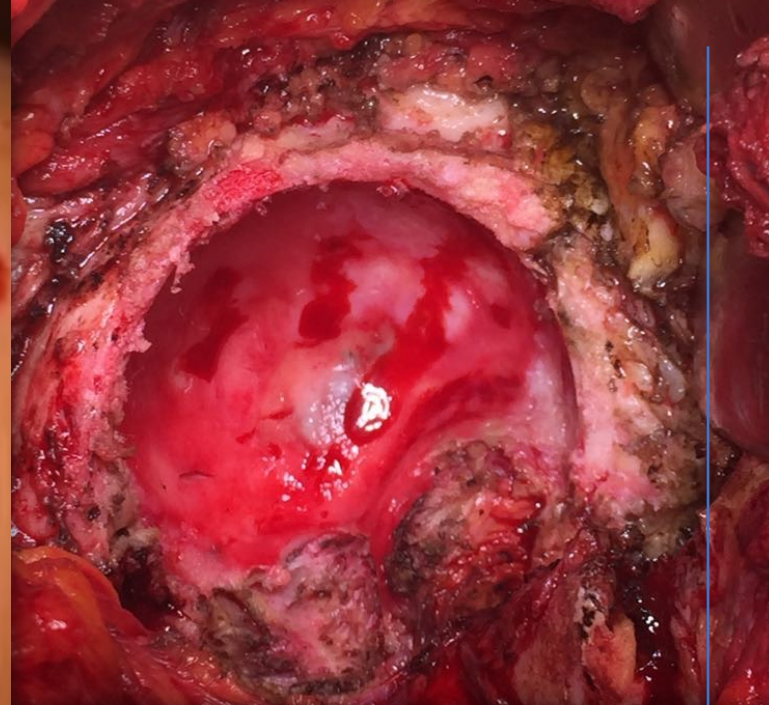
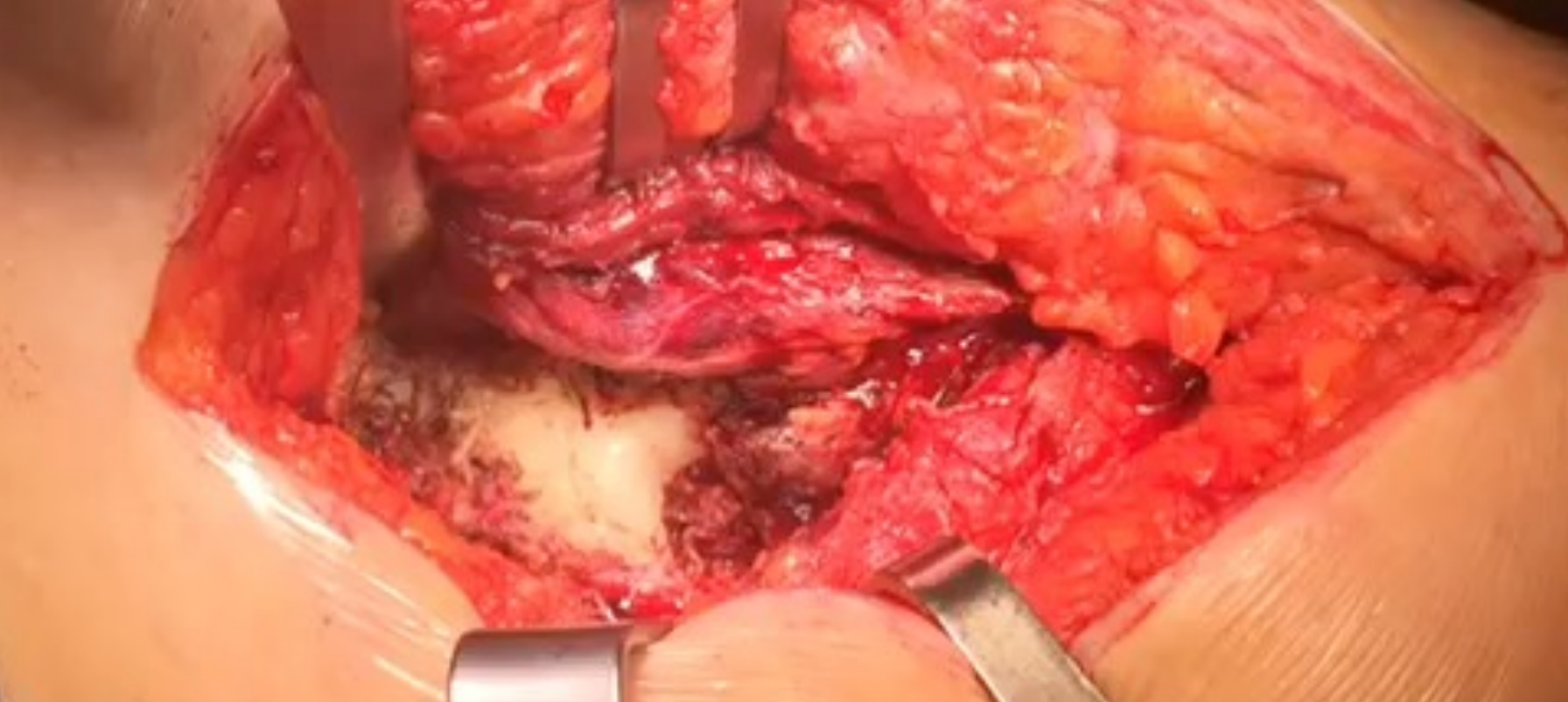
Spacer  
Sizes

Antibiotics  
Selection

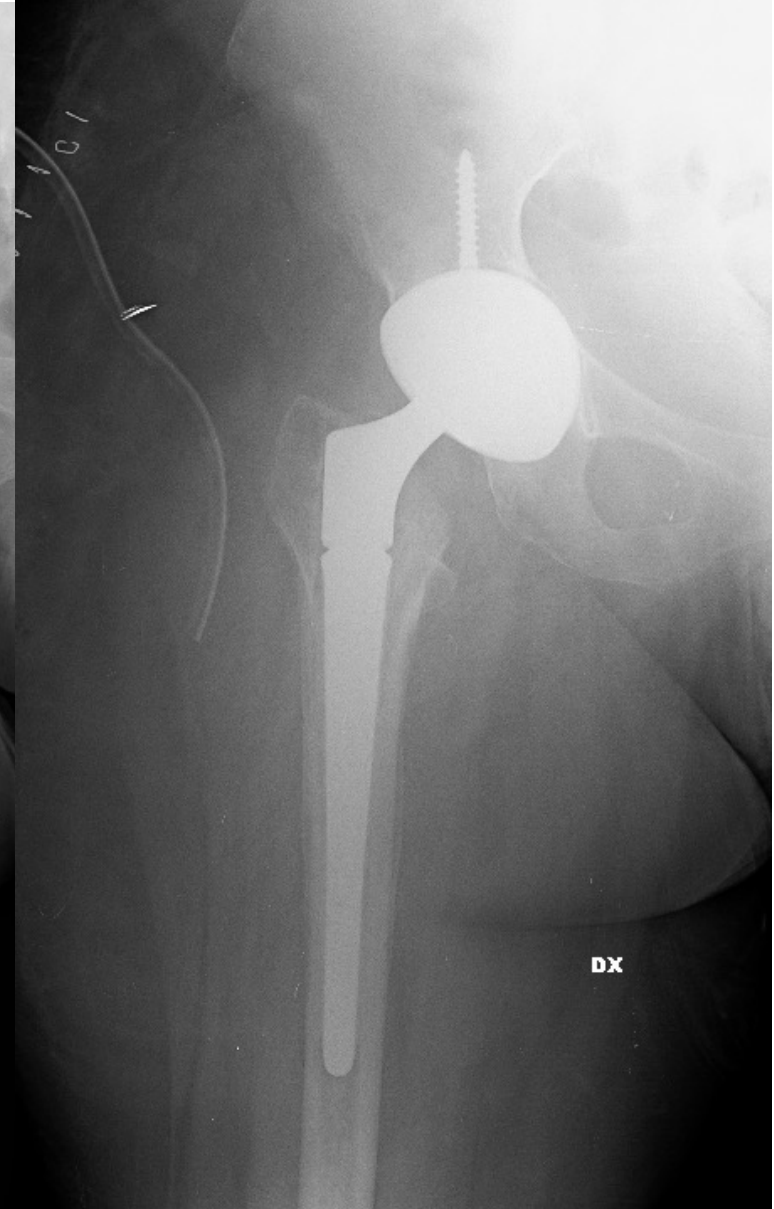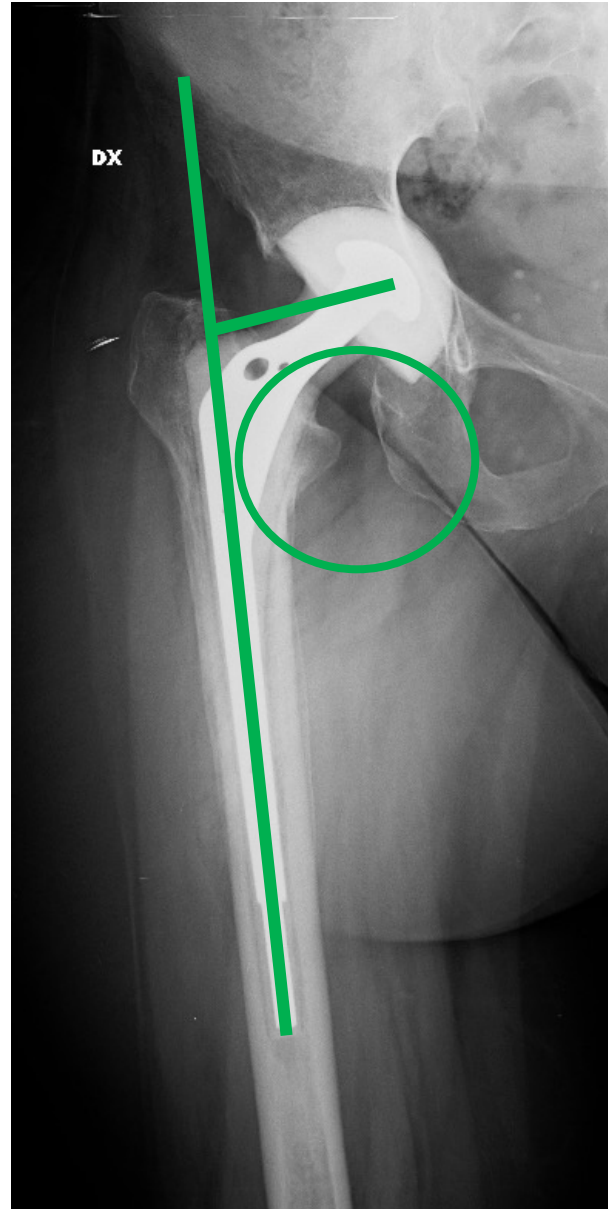
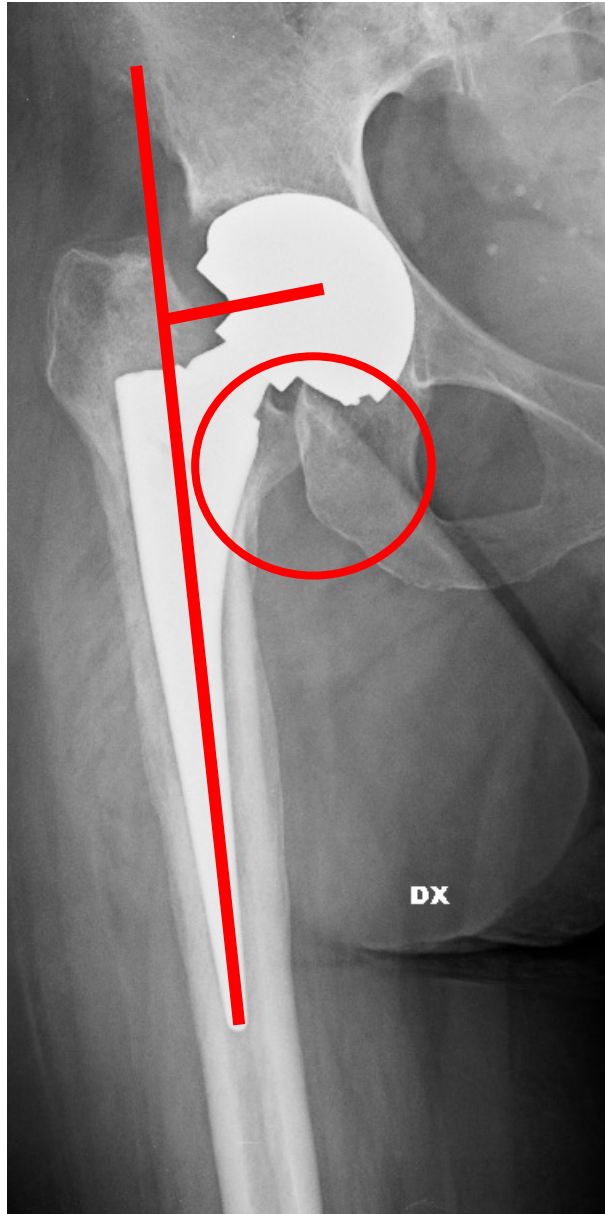
Spacer  
Preparation





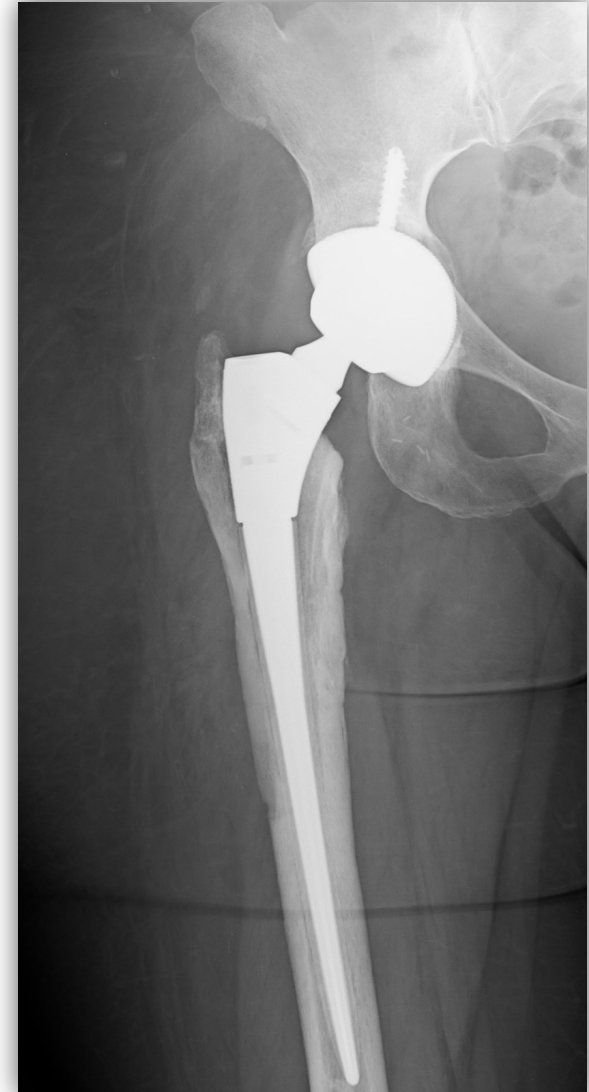
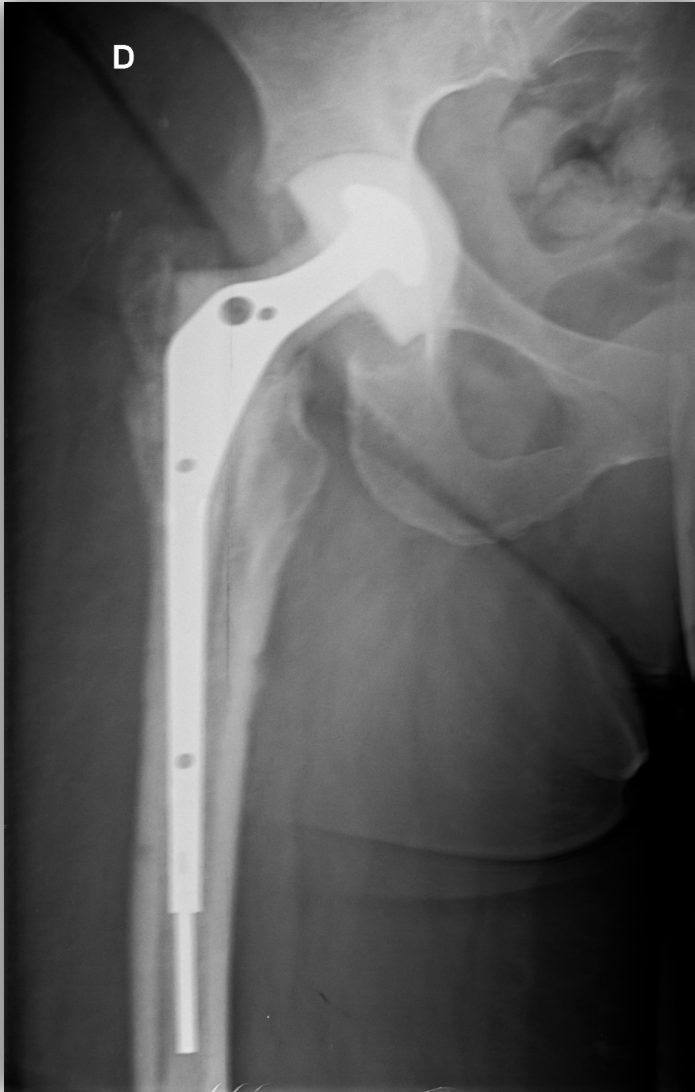
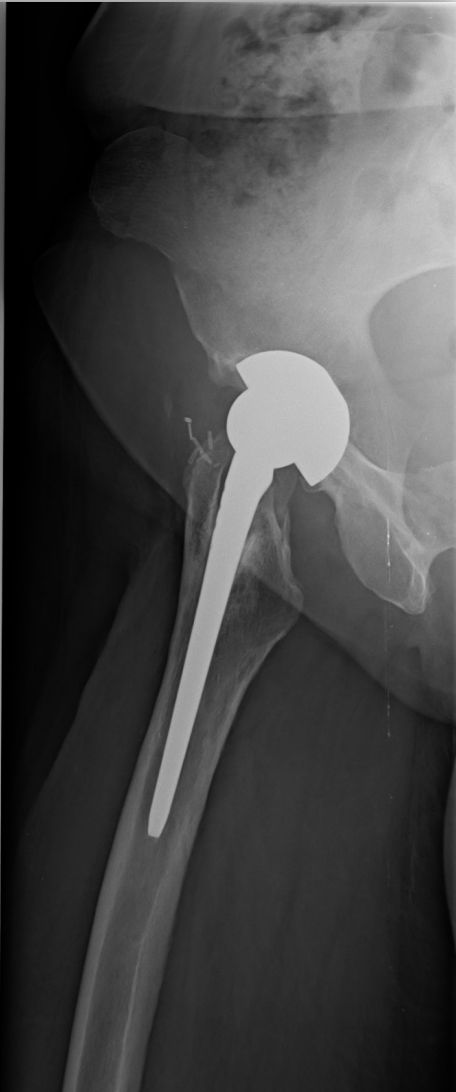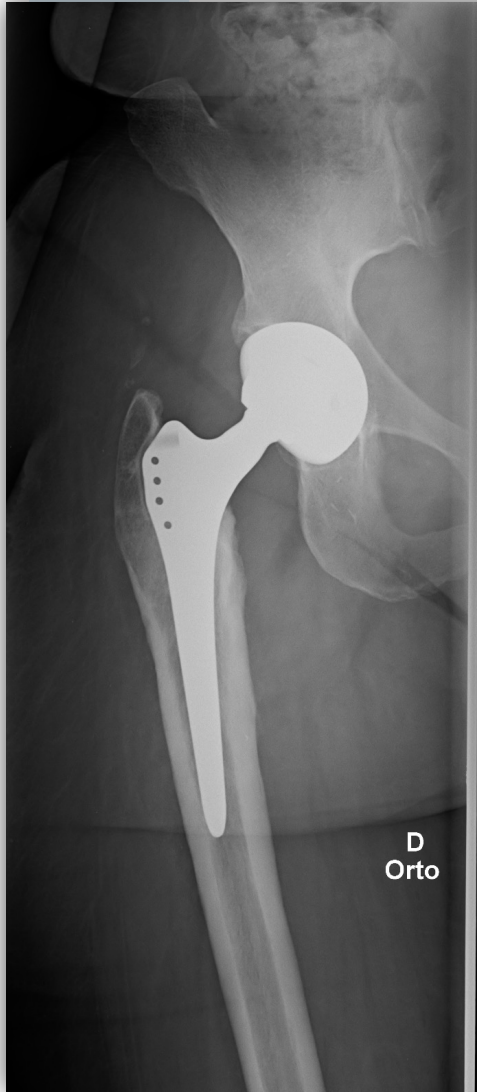- Primary Surgery 3 months ago

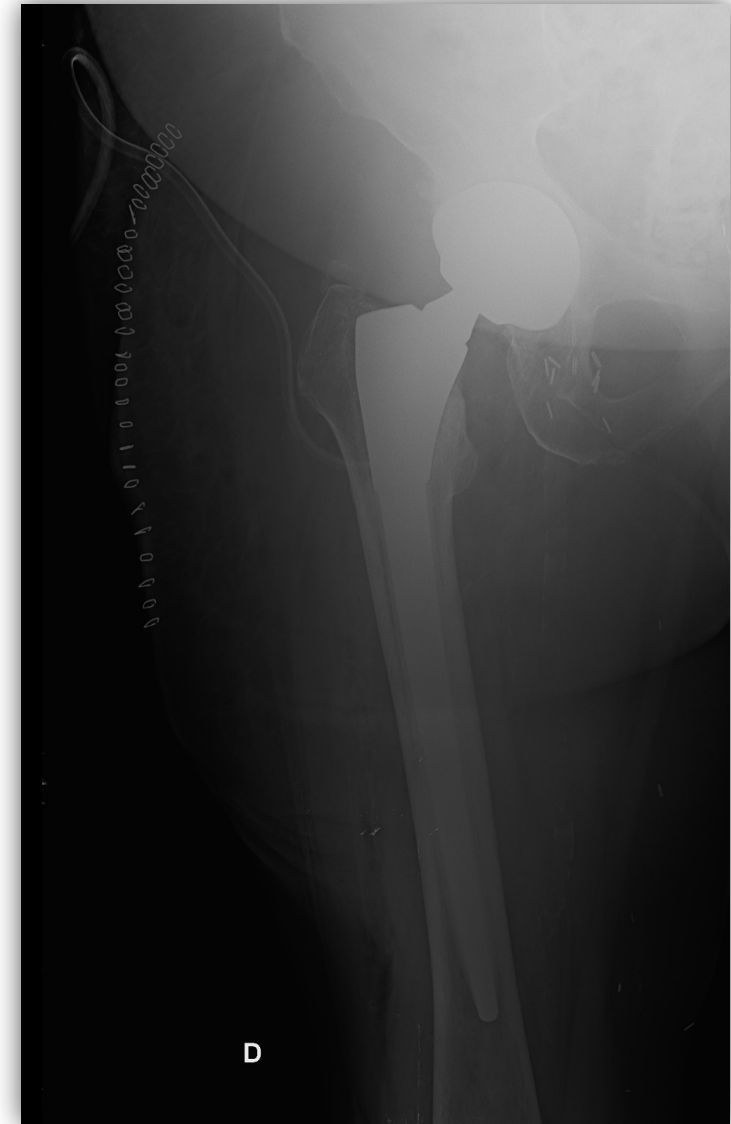
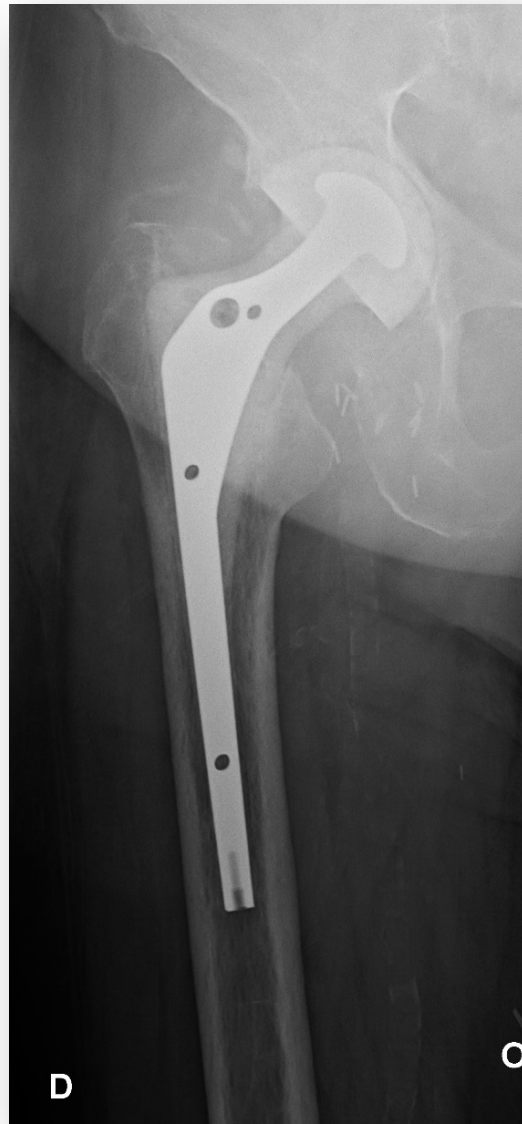
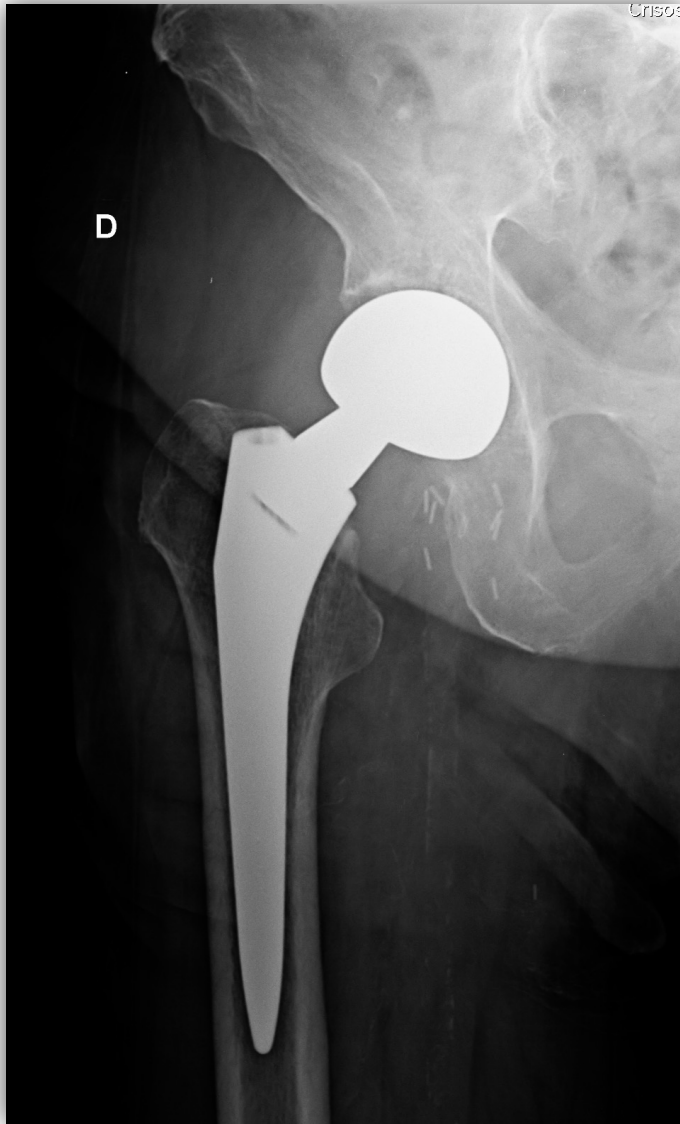
# Case Report: FM, G, 72 y.o.

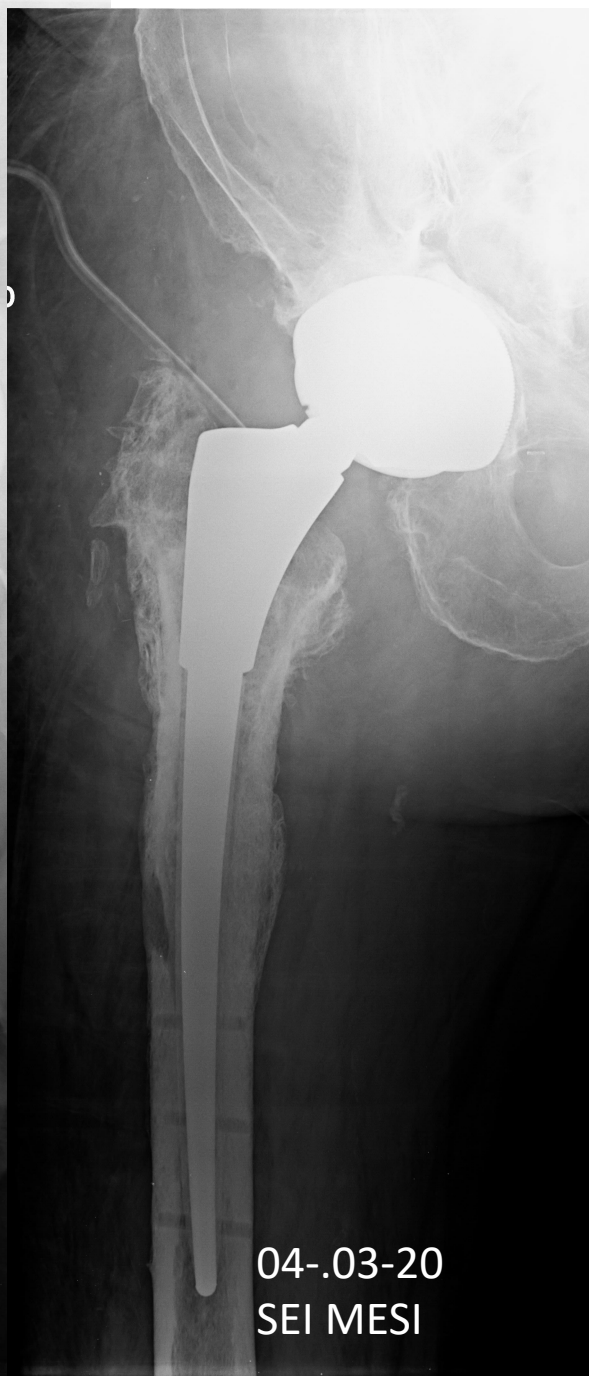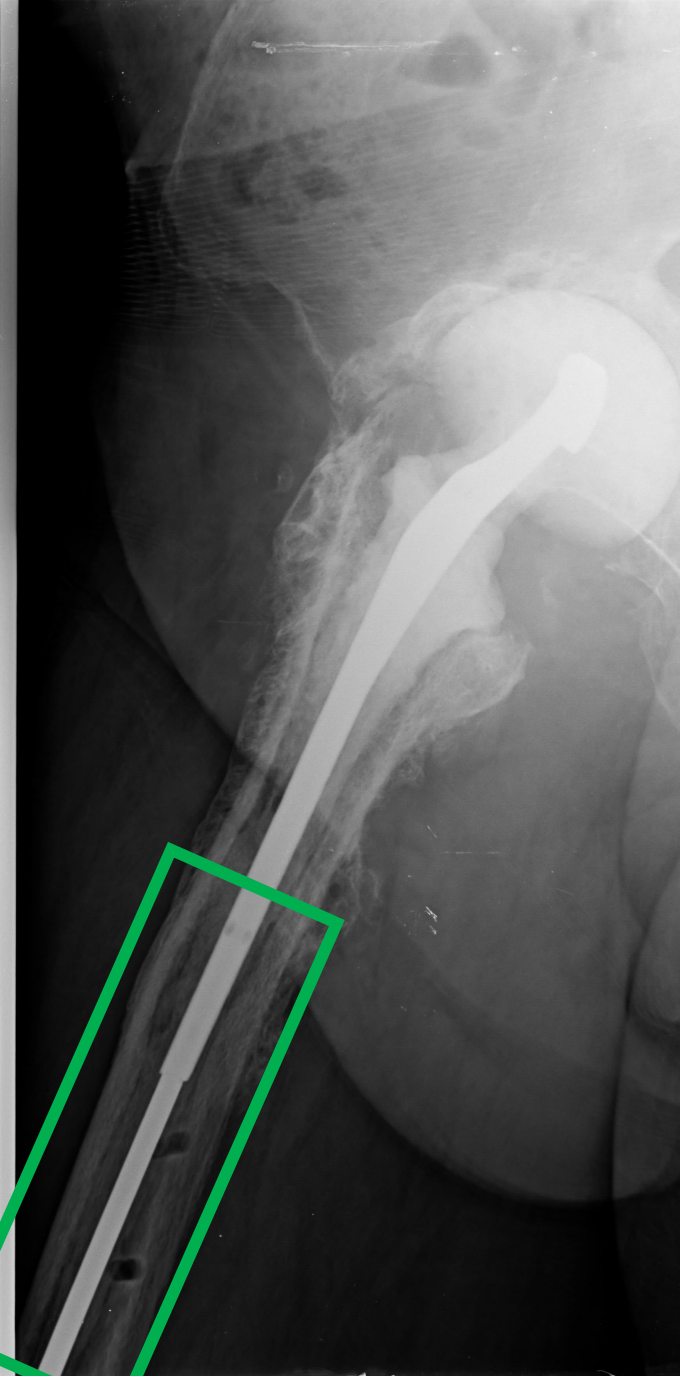
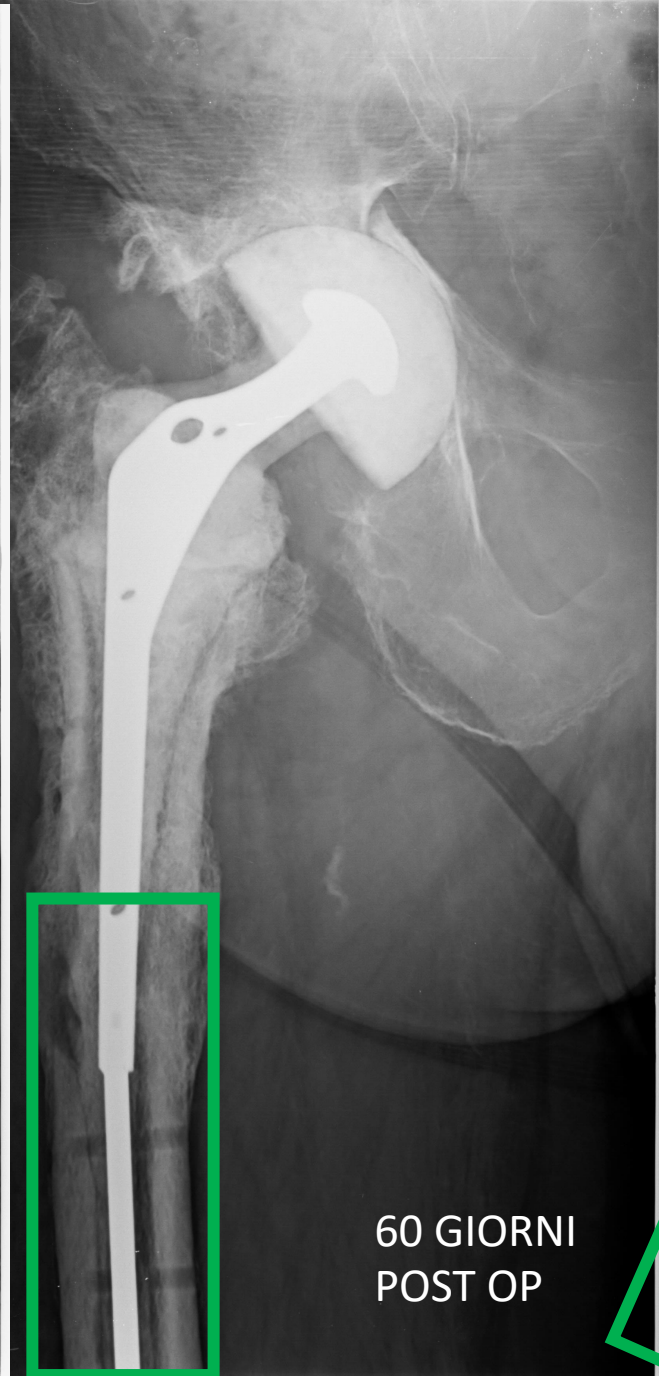
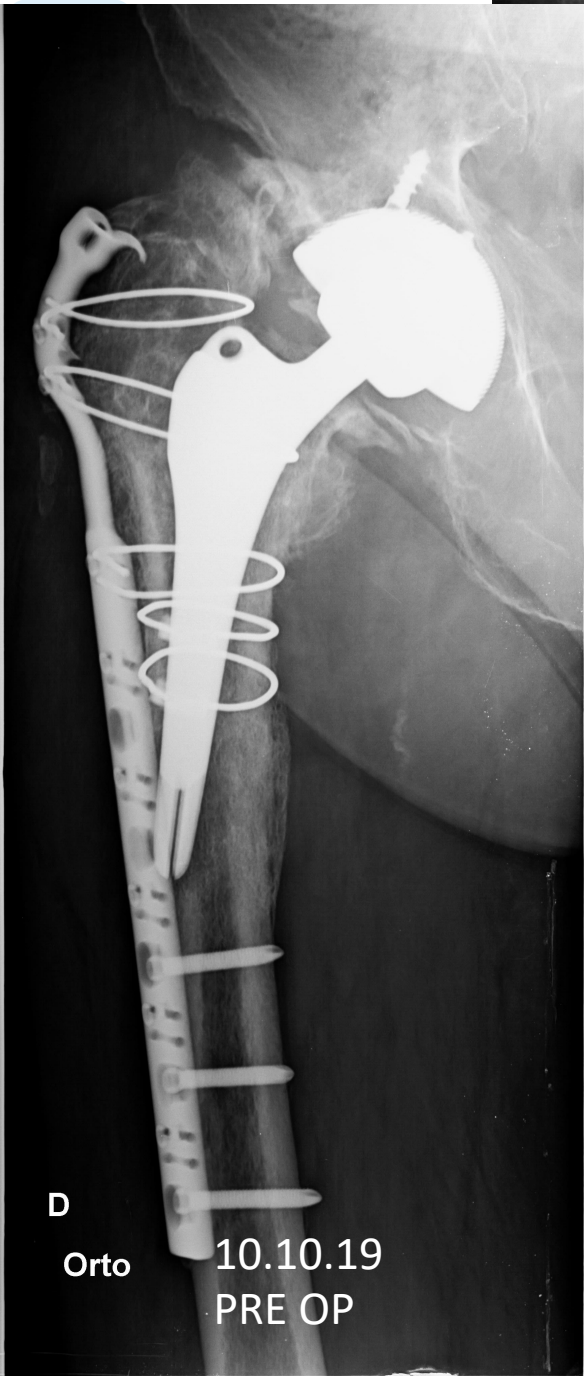- THA 6 months ago



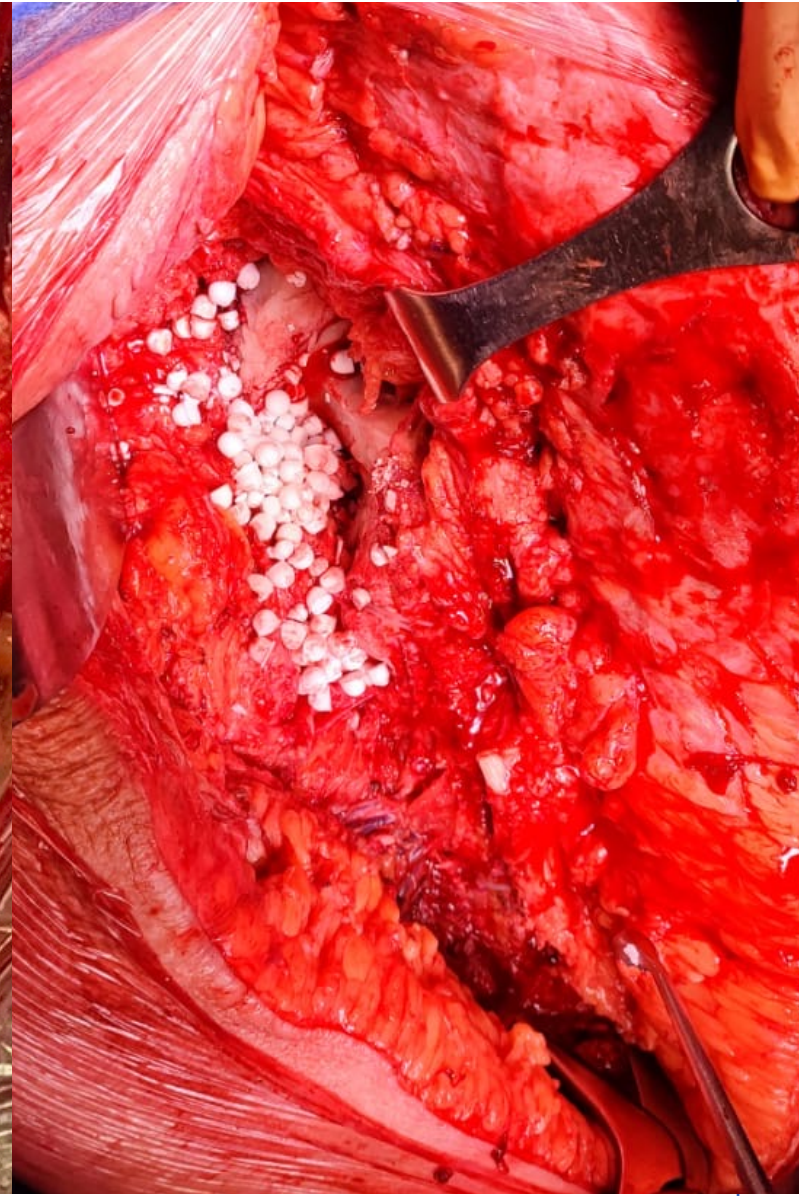
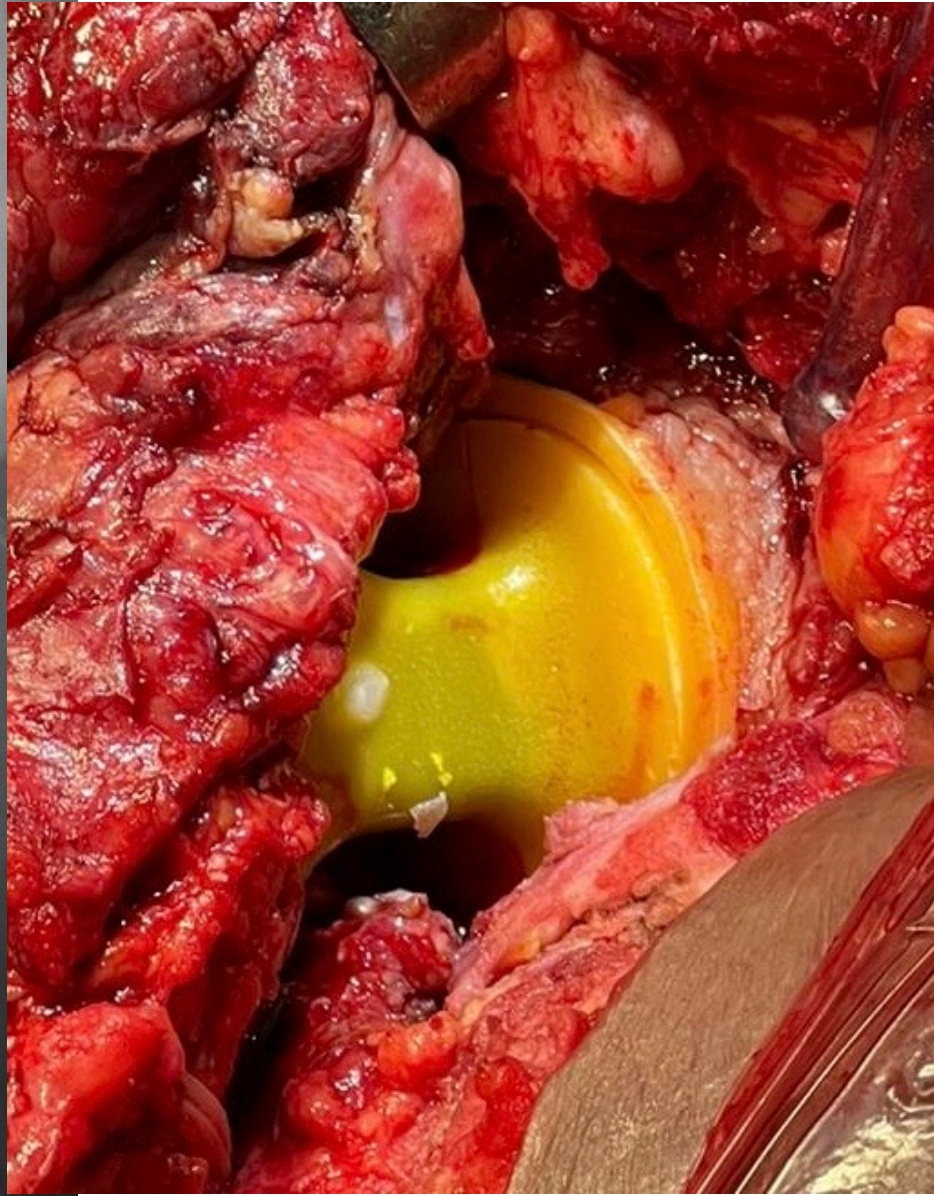
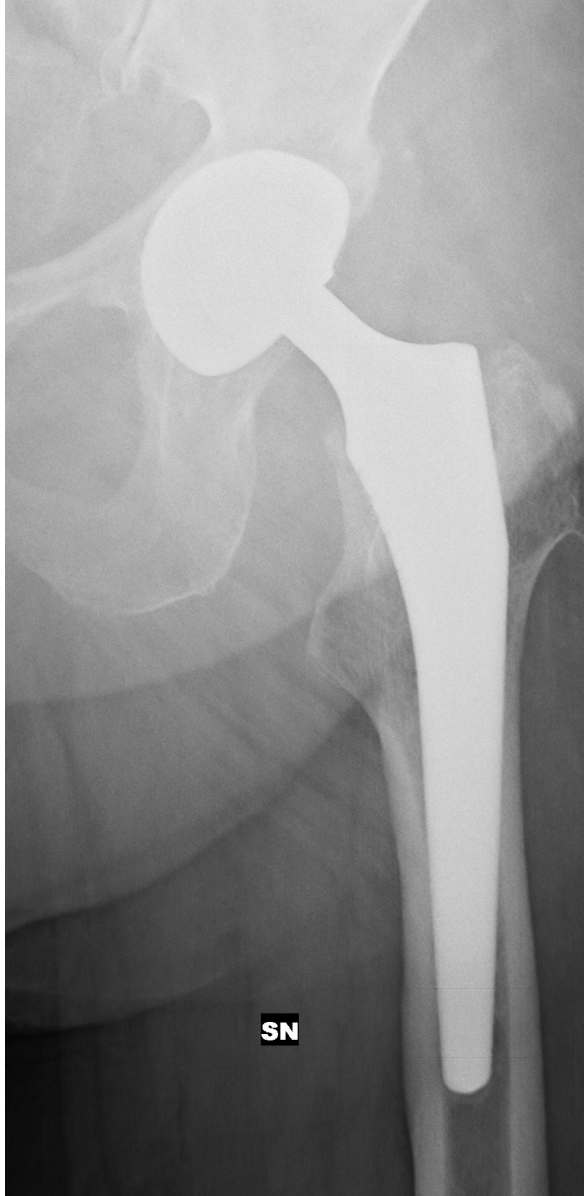- Primary Surgery 2 months ago



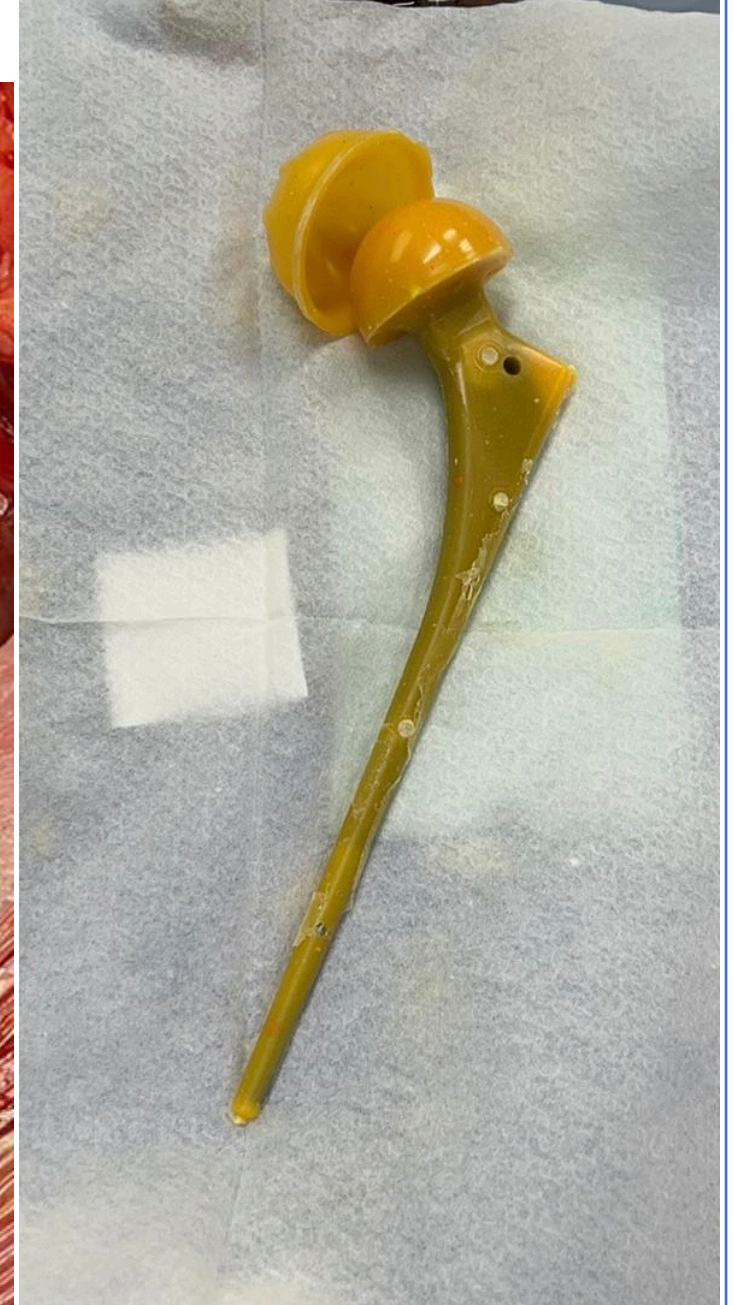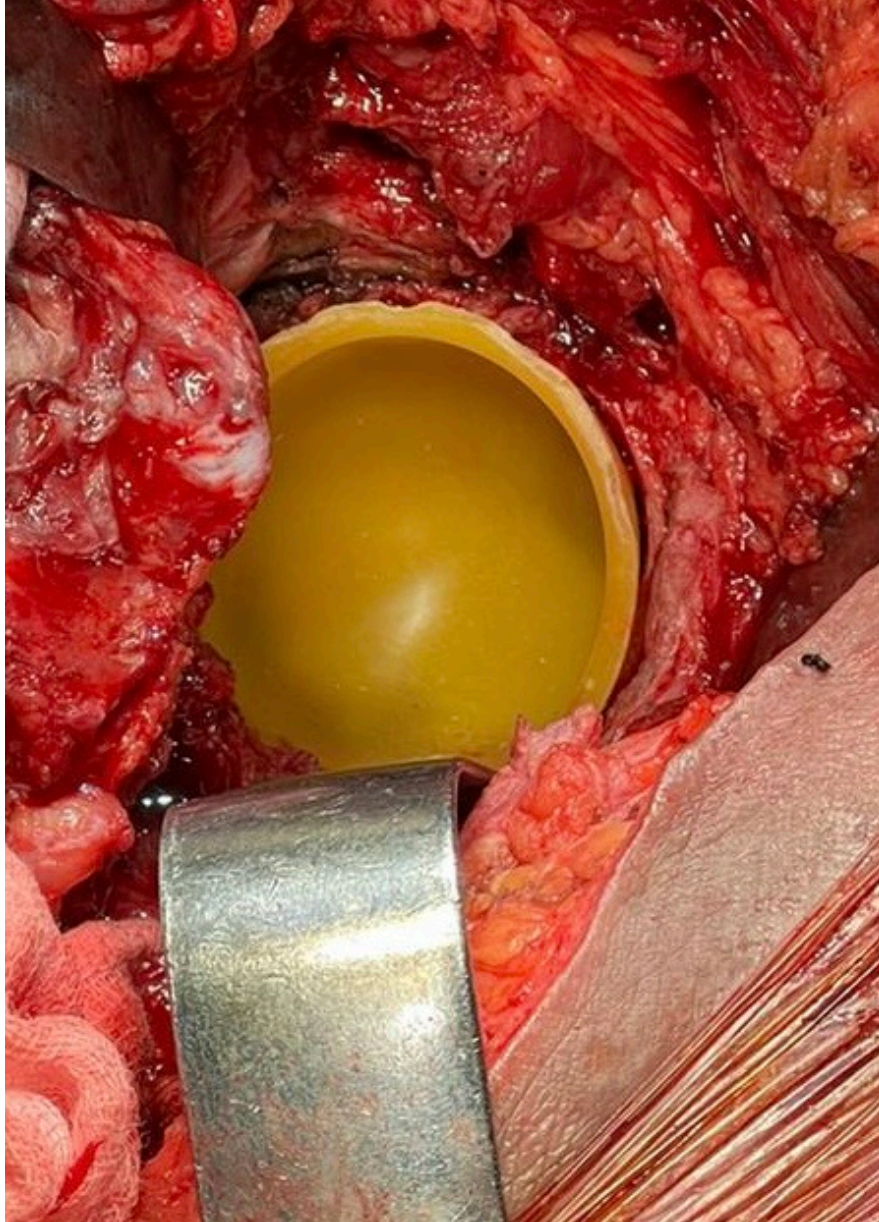




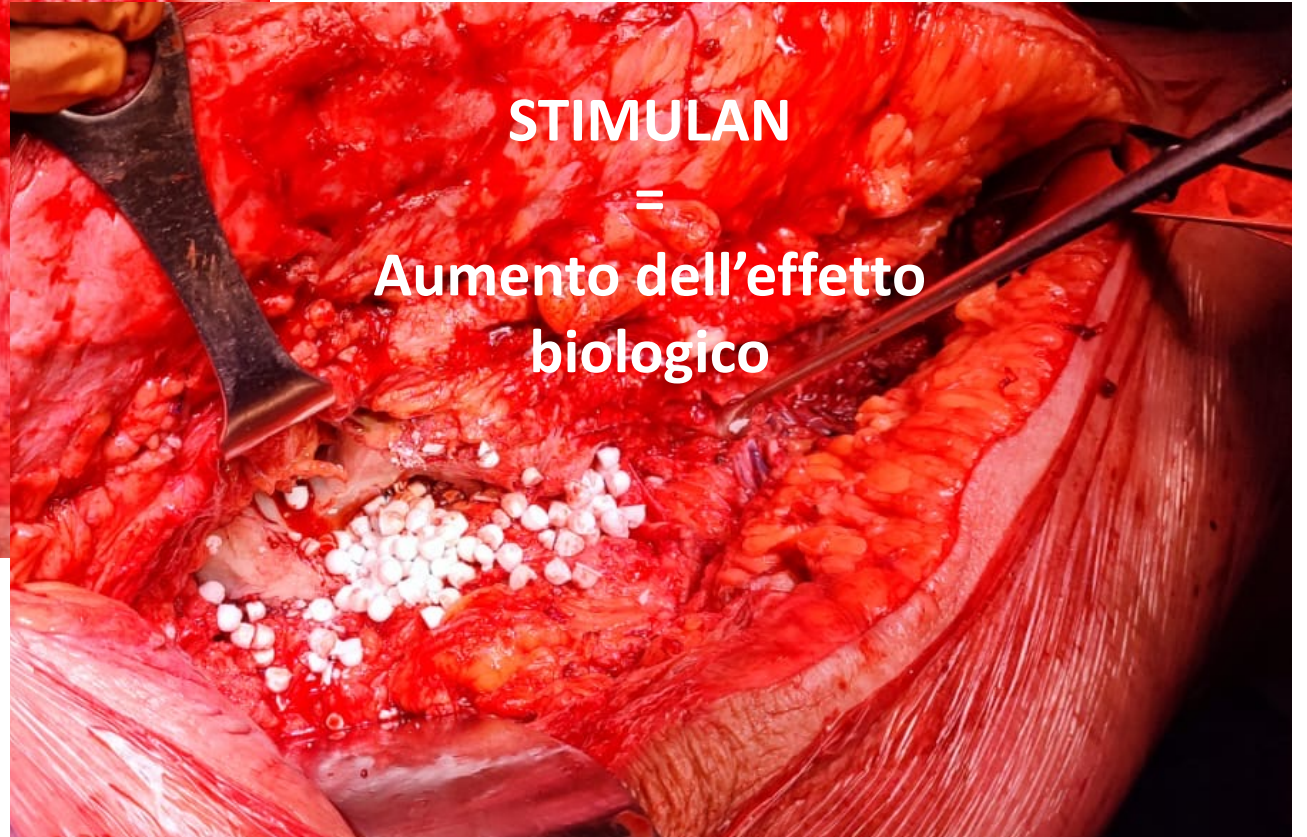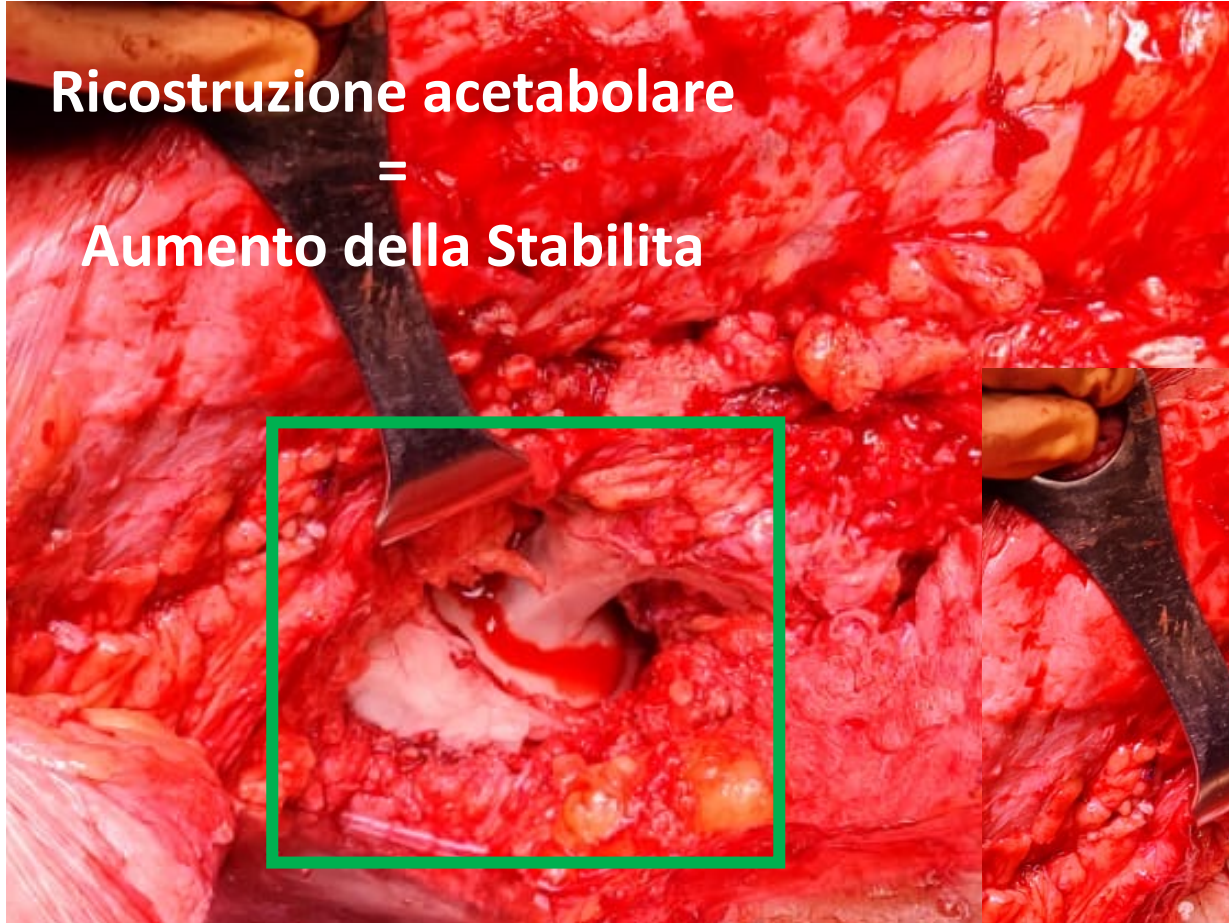
# Complex cases



# Complex cases




# Complex cases





# Space Flex Knee



**DIAMETER:**  
60 mm  
70 mm  
80 mm

**THICKNESS:**  
12 mm  
16 mm  
20 mm

## SpaceFlex Knee

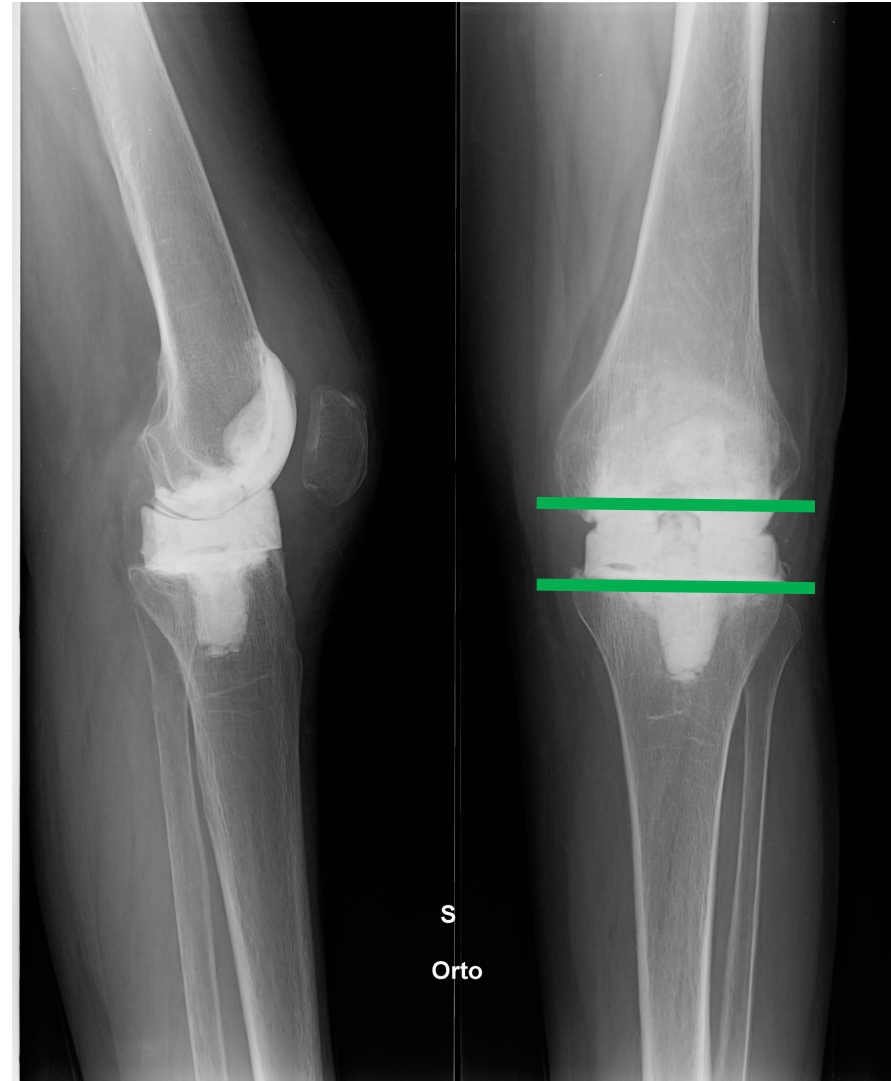
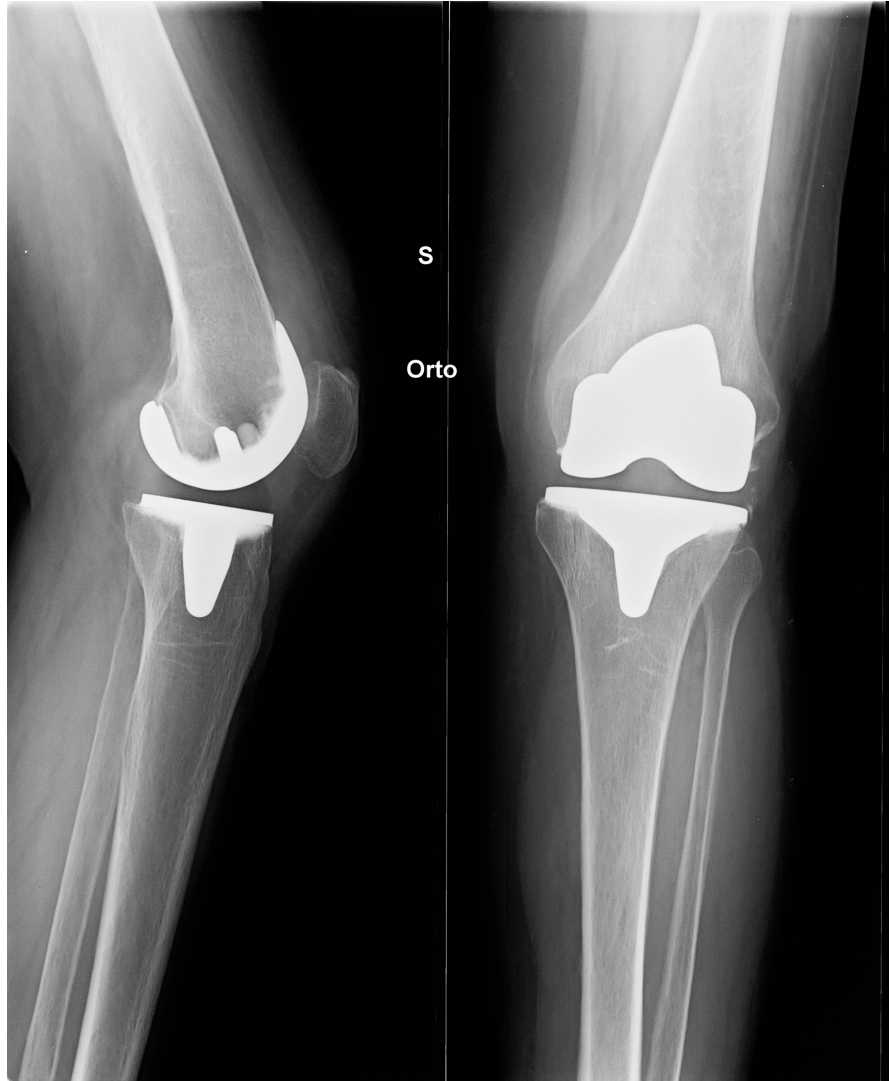
Joint Replacement Unit

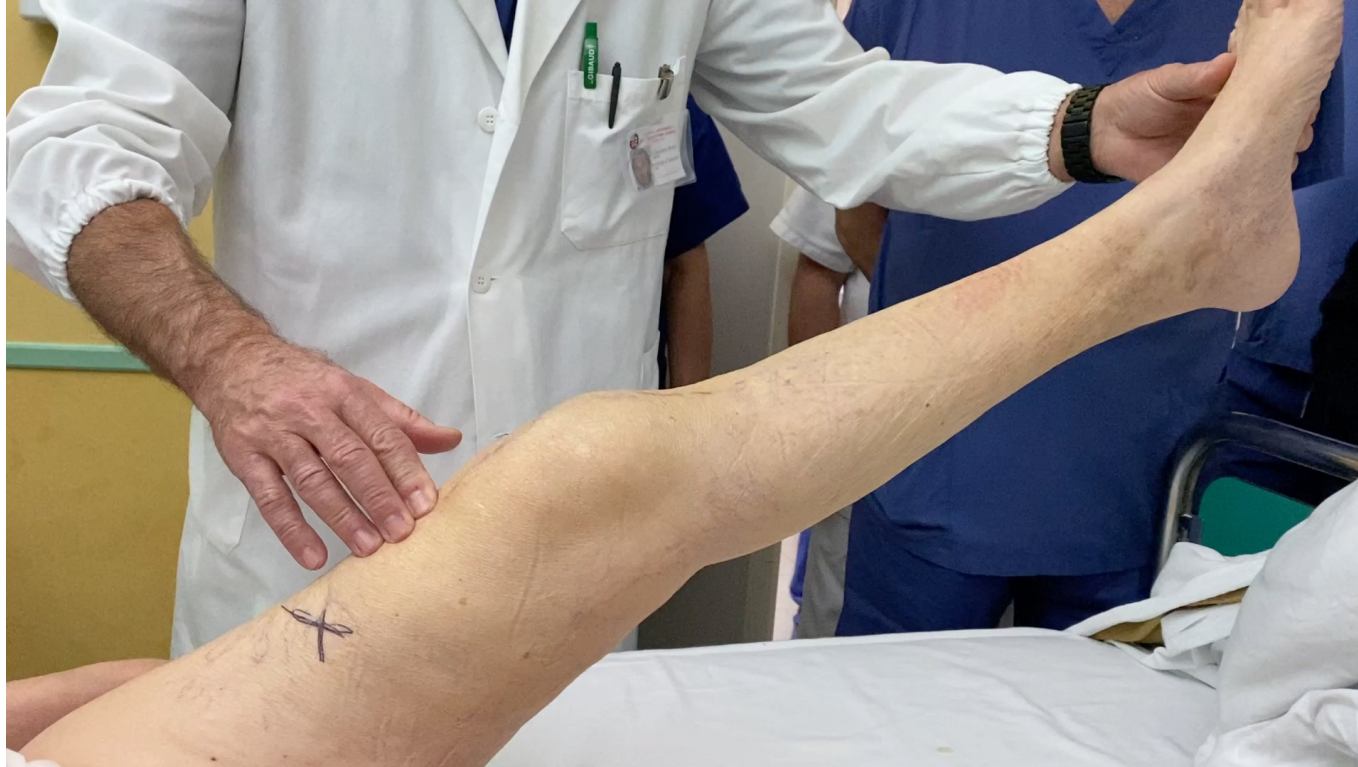# Functional & Essential Instrumentation Set



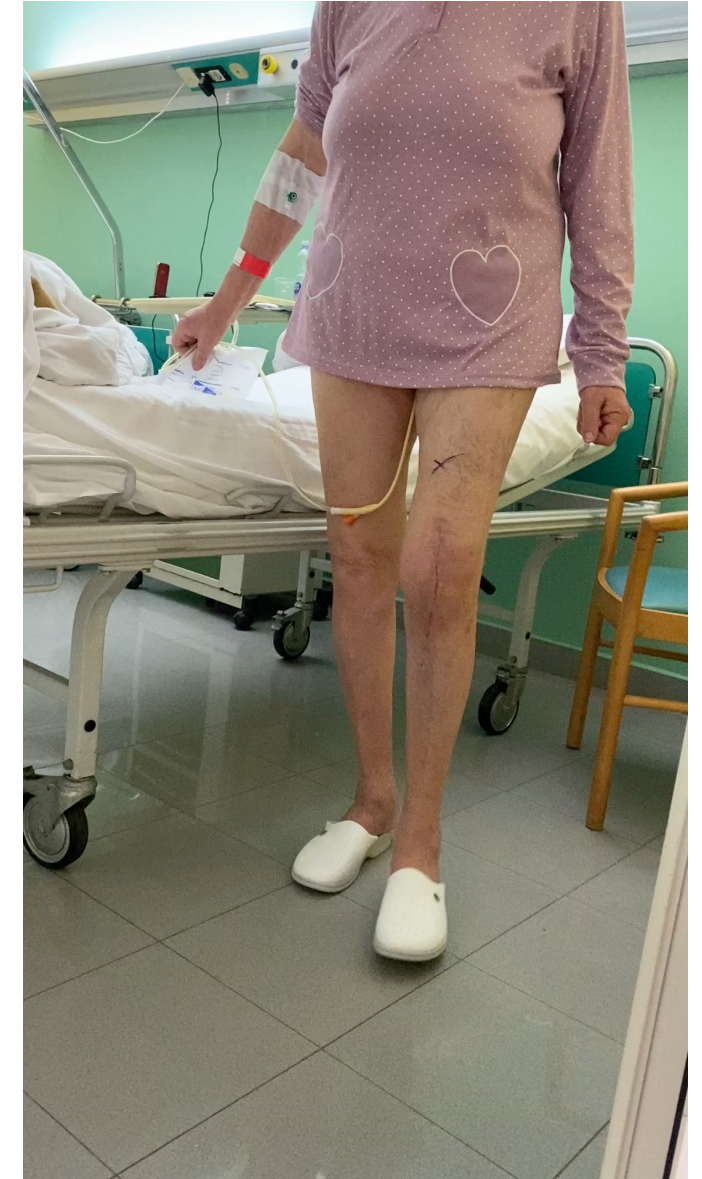# Clinical Case



# Clinical Case

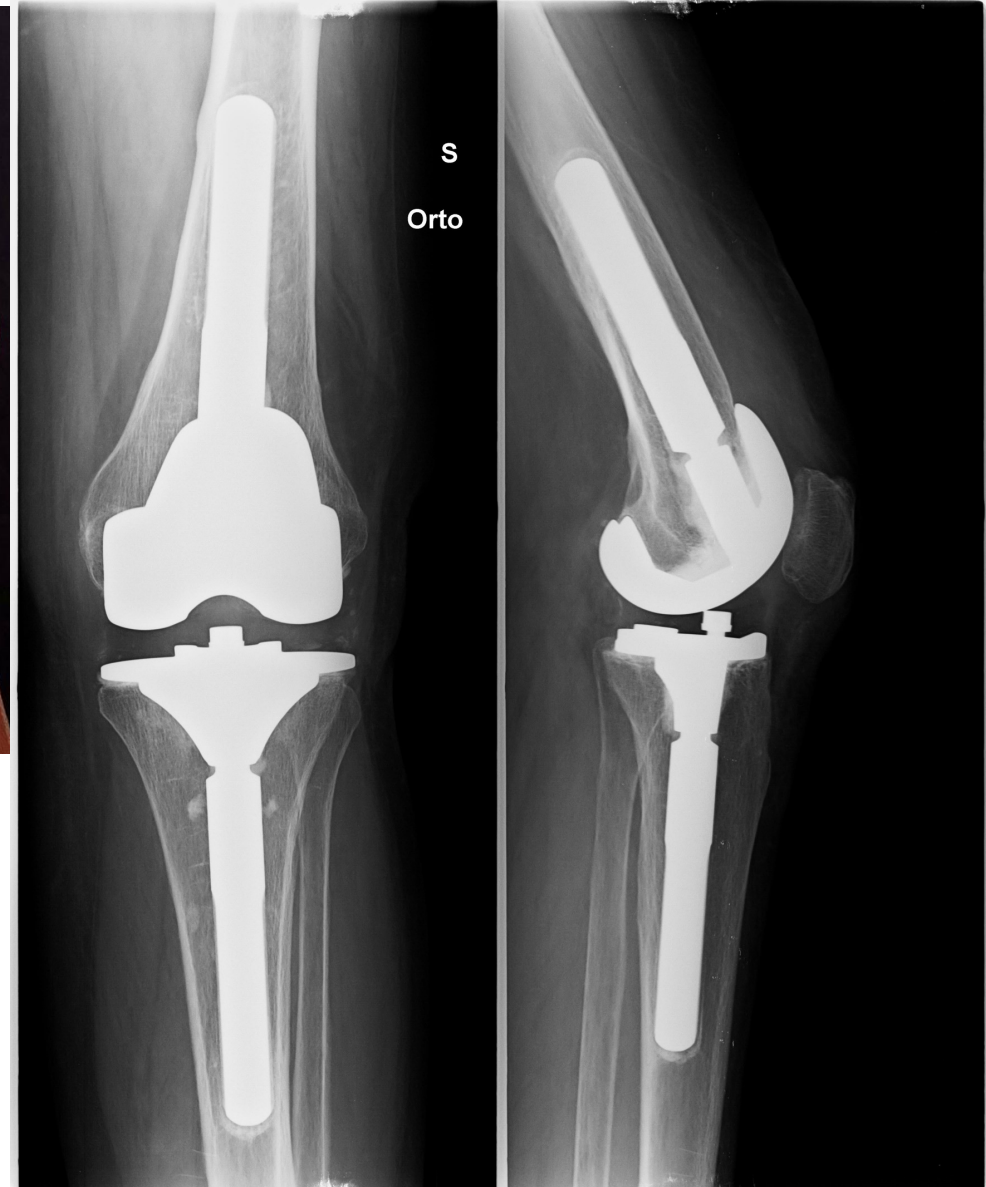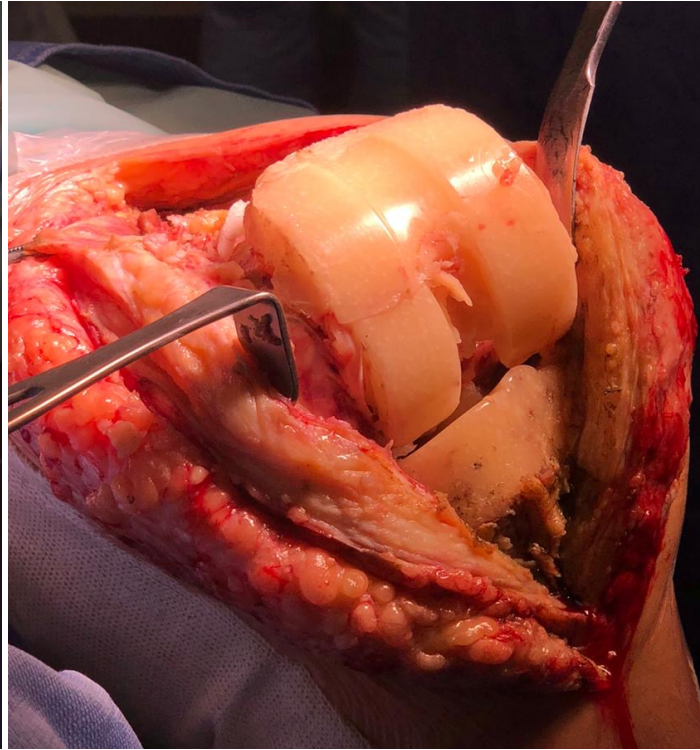
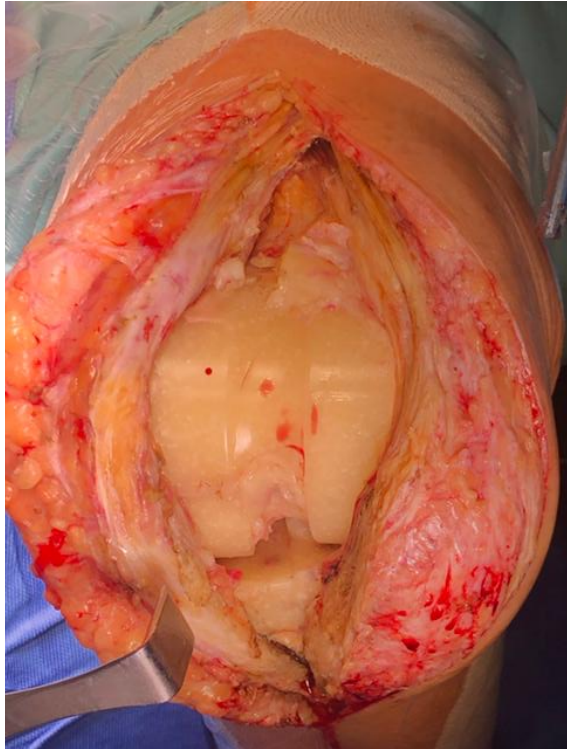


B.R. Female 69 yy Staph Epid – 8 weeks later





# Clinical Cases



B.R. Female 69 yy Staph Epid – 8 weeks later



Thank You For Your Attention

**E ARRIVEDERCI  
A.....**

107° CONGRESSO NAZIONALE DELLA SOCIETÀ  
ITALIANA DI ORTOPEDIA E TRAUMATOLOGIA  
Roma 29-31 Ottobre [www.congressosiot.it](http://www.congressosiot.it)

**SIOT** 20  
**SIOT** 24  
ROMA

